

4-3-2010

Esophago-Pericardial Fistula Following Ablation of the Atrial Fibrillation Focus

Maksim Zayaruzny

University of Massachusetts Medical School

Rana Badr

University of Massachusetts Medical School

Follow this and additional works at: https://escholarship.umassmed.edu/anesthesiology_pubs



Part of the [Anesthesiology Commons](#)

Repository Citation

Zayaruzny, Maksim and Badr, Rana, "Esophago-Pericardial Fistula Following Ablation of the Atrial Fibrillation Focus" (2010). *Anesthesiology and Perioperative Medicine Publications*. 140.

https://escholarship.umassmed.edu/anesthesiology_pubs/140



Esophago-pericardial fistula following ablation of the atrial fibrillation focus

Maksim Zayaruzny MD, Rana Badr MD

Department of Anesthesiology, UMASS Memorial Medical Center



Introduction

- In the past 20 years catheter radiofrequency ablation of atrial fibrillation (RAAF) has become a mainstay in the treatment of refractory atrial fibrillation. While generally safe, serious complications following RAAF have been reported.
- Recent retrospective review of 45,000 cases of catheter ablation reported post-procedure mortality of 0.1 percent.
- Complication rates of 2%-4% have been previously reported. Percutaneous catheter ablation of electrical triggers near the pulmonary vein ostia is associated with 28% incidence of esophageal erythema and 18% incidence of esophageal ulceration
- Patients with atrio-esophageal fistulas and esophageal perforations due to thermal injury can present with non-specific signs and symptoms between 1 and 3 weeks after the procedure and present unusual challenges to the anesthesia provider.
- Atrio-esophageal fistulas and esophageal perforation have been reported to be lethal complications following RAAF. We present a case of successful treatment of late-presenting esophageal perforation after RAAF.

Case presentation

- A 66 year old female with atrial fibrillation refractory to medical treatment and repeated cardioversions had undergone trans-septal RAAF.
- Fourteen days after the procedure the patient presented to the Emergency Department with increasing shortness of breath and chest pain.
- Initial serum lactate was 7.7 with arterial blood pH of 7.15.
- WBS 13.5 (40% bands); HCT 28.9; PLT 718

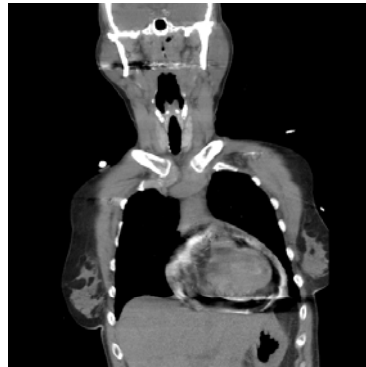


Image 1. Coronal section of the CT scan showing significant pneumopericardium

- On examination the patient appeared in acute distress, with tachycardia, tachypnea, mental status changes, and refractory chest pain.
- Esophageal perforation was suspected and confirmed by radiographic and ultrasonic imaging. (Image 1). Gastrographin extravasation was noted in the lower one-third of the esophagus, at approximately T7-T8 level.
- Transthoracic echocardiography image quality was suboptimal. It demonstrated a moderate pericardial effusion, fibrinous in appearance; no RV/LV collapse was noted.
- The patient was emergently taken to the operating room for left posterolateral thoracotomy and repair of the perforation of the anterior surface of the esophagus with an intercostal muscle pedicle flap.
- After standard ASA monitors, right radial arterial line and right internal jugular triple-lumen catheter were placed.
- Anesthesia was induced with Etomidate (0.2 mg/kg) and Fentanyl (2.5mcg/kg). Rocuronium (1.2 mg/kg) was used to facilitate direct laryngoscopy and 35F double lumen endotracheal tube placement. Anesthesia was maintained with Isoflurane.

- Norepinephrine and Vasopressin infusions were used to maintain hemodynamic stability intra-operatively. Serial arterial blood gas samples were taken to assess the resuscitation efforts.
- Intraoperative findings included a bulging pericardium with approximately 300 mls of purulent fluid. Small area of thermal injury on the anterior surface of the esophagus immediately posterior to the left atrium was identified and covered with an intercostal muscle pedicle flap. Tube thoracostomies were used to widely drain the pericardium and left pleural space.
- After a challenging intra-operative course the patient was transferred to the ICU and subsequently discharged from the hospital in good condition.

Discussion

- According to the data from the Healthcare Cost and Utilization Project (Agency for Healthcare Research and Quality, US Department of Health and Human Services), approximately 49,000 endovascular cardiac ablation/destruction procedures were performed in 2007 (ICD-9-CM code 37.34).
- Thermal esophageal injury leads to the development of unique physiologic conditions, which make the delivery of anesthesia particularly challenging.
- Patients may present with components of both sepsis (decreased SVR, hypermetabolism, and high levels of circulating catecholamines) and pericardial tamponade (increase in intrapericardial pressure leading to decreased cardiac output, restriction of cardiac filling). Catastrophic hemodynamic instability may develop during induction of anesthesia, irrespective of the IV induction agent. Preparations for an immediate surgical incision must be made prior to the induction of anesthesia.

- Surgical repair of esophageal perforation is done through a thoracotomy approach, requiring insertion of a double lumen endotracheal tube for lung isolation, which could be challenging in an emergent situation with an unstable patient and full stomach.
- While no RV/LV collapse was noted on the initial echocardiogram, surgical drainage of the pericardium resulted in a significant hemodynamic improvement. During the initial phase of tamponade, in the absence of the overt clinical signs, exaggerated respiratory variation in the left ventricular systolic ejection time may be a subtle finding.
- Hypotension in this patient was related both to tamponade physiology and sepsis secondary to purulent pericarditis, which developed following esophageal perforation. Hemodynamic support was required to increase preload and afterload. We choose to use norepinephrine and vasopressin due to septic presentation of the patient and administered mixture of colloid and crystalloids to augment preload.

Bibliography

1. Cappato R, et al. Prevalence and causes of fatal outcome in catheter ablation of atrial fibrillation. *J Am Coll Cardiol.* 2009 May 12;53(19):1798-803
2. O'Hara GE, et al. Catheter ablation for cardiac arrhythmias: a 14-year experience with 5330 consecutive patients at the Quebec Heart Institute, Laval Hospital. *Can J Cardiol.* 2007 Oct 23; Suppl B:67B-70B
3. Konda A, et al. Esophageal ulceration from high-intensity focused US catheter ablation for pulmonary vein isolation: a novel complication in the treatment of symptomatic refractory atrial fibrillation. *Gastrointestinal Endoscopy* 2008 Vol 68, No3: 597-599
4. Bahnson TD. Strategies to minimize the risk of esophageal injury during catheter ablation for atrial fibrillation. *Pacing Clin Electrophysiol.* 2009 Feb;32(2):236-60
5. <http://hcupnet.ahrq.gov> (Accessed March 10, 2010)
6. Wayne VS, et al. Dynamic effects of pericardial effusion without tamponade: respiratory responses in the absence of pulsus paradoxus. *Br Heart J* 1984;51:202-204