

3-24-2012

Management of a Patient with an Encapsulated Parapneumonic Empyema Complicated by the Intraoperative Development of an Acute Bronchopleural Fistula and ARDS

Nancy Lee

University of Massachusetts Medical School

Stephen O. Heard

University of Massachusetts Medical School

Follow this and additional works at: https://escholarship.umassmed.edu/anesthesiology_pubs



Part of the [Anesthesiology Commons](#), and the [Respiratory Tract Diseases Commons](#)

Repository Citation

Lee, Nancy and Heard, Stephen O., "Management of a Patient with an Encapsulated Parapneumonic Empyema Complicated by the Intraoperative Development of an Acute Bronchopleural Fistula and ARDS" (2012). *Anesthesiology and Perioperative Medicine Publications*. 114.

https://escholarship.umassmed.edu/anesthesiology_pubs/114



Management of a Patient with an Encapsulated Parapneumonic Empyema Complicated by the Intraoperative Development of an Acute Bronchopleural Fistula and ARDS

Nancy Lee B.A., Stephen O. Heard M.D.

Department of Anesthesiology, University of Massachusetts Medical School Worcester, MA



Introduction

Parapneumonic abscess is associated with a mortality of about 5-20% in the general patient population and increases to over 50% for patients who are elderly or have comorbid conditions¹. When parapneumonic abscesses become organized, thoracotomy and decortications are indicated for adequate drainage and to allow for maximal lung re-expansion². Bronchopleural fistula (BPF), a communication between the bronchial tree and the pleural space, is associated with significant morbidity and mortality. Although rare, BPF remains a serious complication of thoracic surgery and poses significant challenges to intraoperative respiratory management³⁻⁵. While multiple surgical and medical management strategies for BPF have been described through various case reports and retrospective studies, no controlled studies exist comparing the various treatment modalities and there are no established guidelines for the management of patients with BPF³. BPF that develops secondarily to surgical parapneumonic abscess drainage represents a challenging and complex management problem.

Case Report

A 62-year-old male patient with a right encapsulated parapneumonic empyema presented for a right thoracotomy and decortications. Past medical history was significant for severe aortic stenosis, COPD, gastric cancer in remission, and chronic anemia and cachexia and increased dyspnea. In preparation for surgery, an arterial catheter and two large bore peripheral IVs were inserted. Following induction of general anesthesia, the patient was intubated with an 8.5 endotracheal tube (ETT) under general anesthesia and ventilated with positive end expiratory pressures (PEEP). A preoperative flexible bronchoscopy was performed to ensure that there was not an overabundance of secretions and that single lung ventilation during the decortications could be tolerated. No gross abnormalities of the carina or main bronchi were observed. After withdrawal of the bronchoscope, a left sided double lumen endotracheal tube (DLT) was inserted. Confirmation of proper placement was made with bronchoscopy. Following right lung isolation decortication was begun. Multiple parenchymal avulsions occurred during decortication demonstrating the fragility and friability of the tissue. Subsequently, the patient's oxygenation began to decrease. At this point, it was determined that the DLT had migrated and could not be repositioned correctly. The DLT was changed for a single lumen ETT and ventilation and oxygenation were restored. The decortication proceeded and a large abscess was drained of about 250-300mL of purulent fluid. Because of the necrotic and deeply adherent nature of the rind around the abscess, the decortication was left incomplete. During the decortication, oxygen saturations were difficult to maintain with an average saturation in the 80% range despite frequent suctioning of secretions and the use of 100% oxygen. In addition, the patient developed septic shock requiring the use of vasopressors for blood pressure support. Four chest tubes were placed on the right side and the tissues were well approximated at the close of the surgery. Significant air leaks were noticeable in the underwater seal draining the chest tubes during both inspiratory and expiratory phases and a BPF was diagnosed. Ventilation remained difficult with oxygen saturations remaining in the 70-85% range. To improve oxygenation, independent lung ventilation (ILV) was planned. The ETT was changed to a DLT with a tube changer and the position was confirmed with bronchoscopy. While ventilation and oxygenation improved initially with ILV, the patient eventually died.

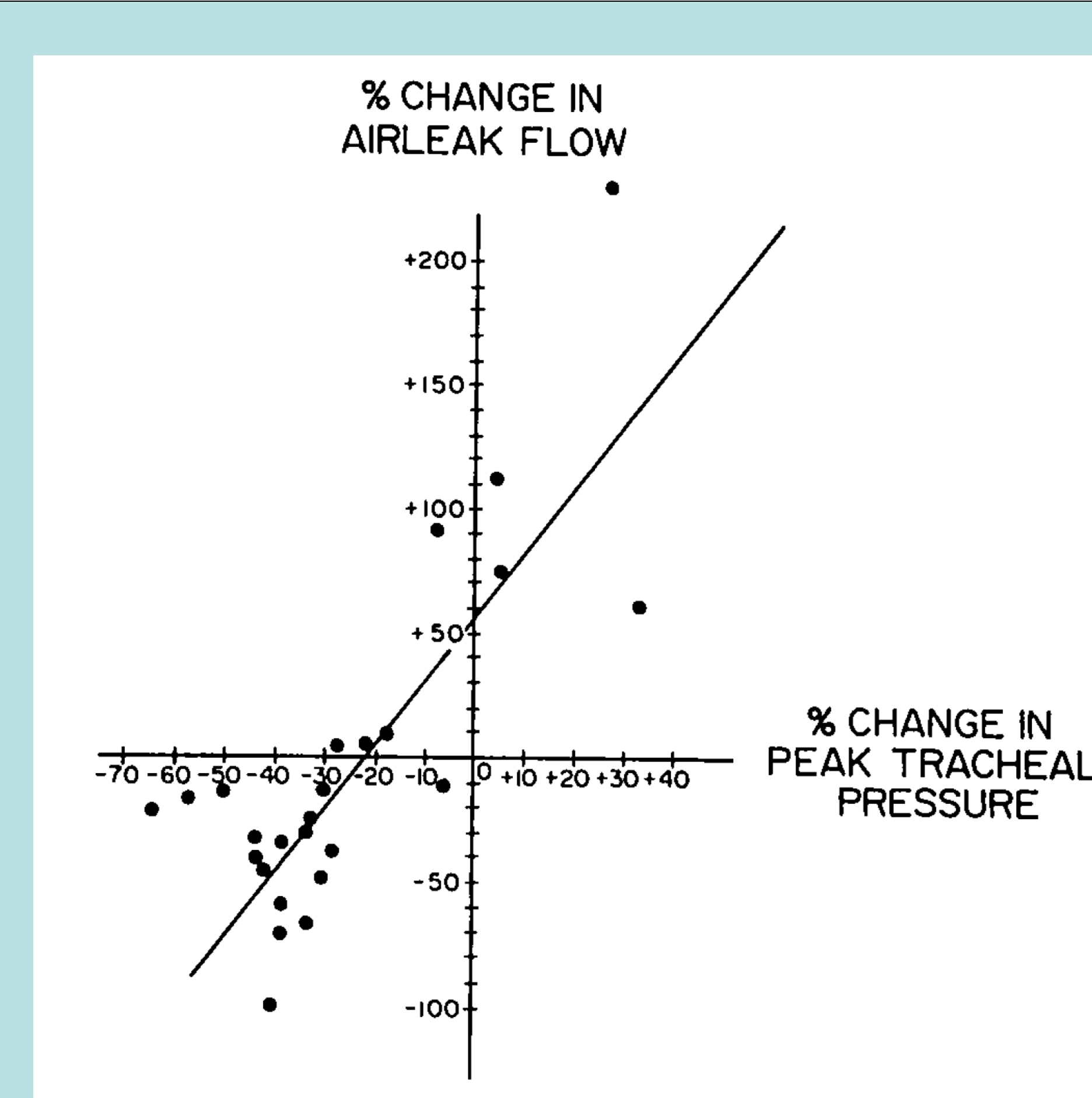


Figure 1. Relationship of the percent change in the BPF air leak flow to the percent change in peak tracheal pressure resulting from the substitution of HFJV for conventional mechanical ventilation¹⁰.

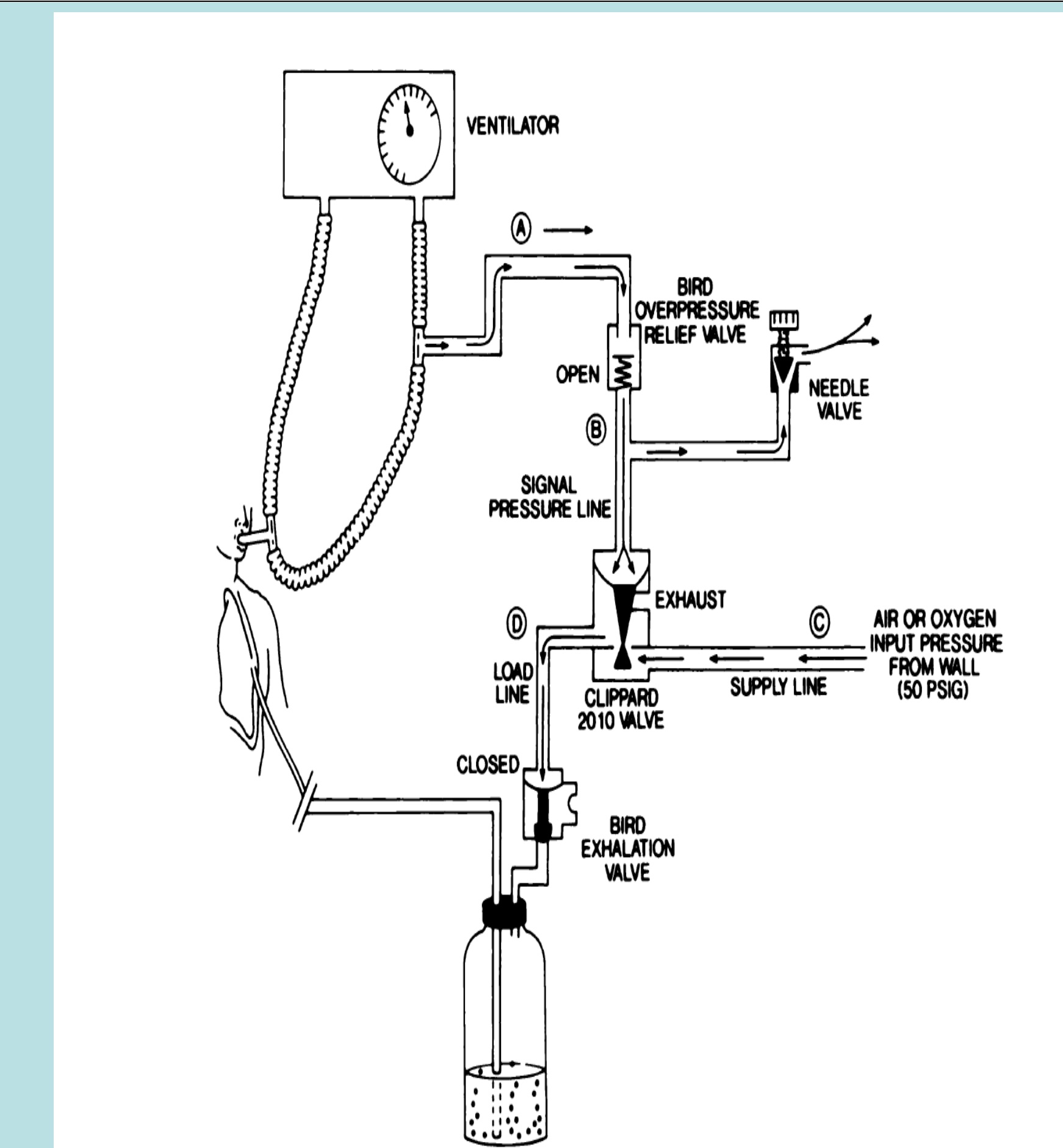


Figure 2. During the exhalation phase, airway pressure decreases which causes the overpressure relief valve to close. The pressure loading diaphragm (A) in the amplifier valve dissipates via a needle valve, which closes the amplifier valve. Thus, the exhalation valve opens and allows the chest tube and the underwater seal apparatus to function in the normal manner¹².

Discussion

We report the use of ILV in a patient with severe underlying parenchymal disease who developed BPF after thoracotomy and decortication of an empyema with subsequent development of acute respiratory distress syndrome (ARDS). While a great majority of patients with either ARDS or BPF can be successfully managed with conventional ventilation strategies, the additional management challenges presented by BPF in the setting of ARDS and sepsis often necessitate the utilization of alternative ventilation strategies such as ILV, high frequency ventilation (HFV), and extracorporeal support. Adjuncts to these strategies such as flexible bronchoscopy, tracheobronchial stents, PEEP to the chest tube, and timed occlusion of chest tubes have been described in case reports with variable success.

Recommendations from several case reports and studies suggest that BPF management should focus on decreasing air leak across the fistula and promote healing through employing ventilation strategies that emphasize decreasing airway pressure and alveolar distension, minimizing pleural suction while maintaining lung expansion, weaning from positive pressure ventilation, and avoidance of alveolar hyperinflation. In the management of ARDS, the recruitment of abnormal areas of noncompliant atelectatic lung is necessary to improve oxygenation and minimize intrapulmonary shunting. Traditionally, this is achieved through conventional positive pressure ventilation with a single lumen endotracheal tube and increased tidal volume and PEEP. Because the strategies for management of BPF and ARDS are often contradictory, it is necessary to tailor ventilation to each patient.

Independent lung ventilation with differential PEEP has been reported by numerous case reports and studies as a method to restore alveolar volume and oxygenation while promoting healing and closure of bronchopleural fistulas⁶⁻⁸. ILV employs a DLT and two mechanical ventilators to anatomically and physiologically isolate each lung for individual ventilation, allowing for differential PEEP, tidal volume, inspiratory flow, and FiO₂. While ILV is usually a second line strategy in ventilation management in patients in which conventional ventilation has failed, ILV was anticipated in this patient due to his severe parenchymal lung disease, the parenchymal injuries anticipated in thoracotomy and decortication, and his recent pneumonia for which anatomical lung isolation would be beneficial in preventing contamination of the non-operative lung. Challenges in using ILV include the imperative of maintaining correct DLT position (which is often difficult) and pulmonary toilet (secretion clearance may be difficult due to the small size of the endolumen).

High frequency ventilation, another alternative strategy for management of BPF, has been advocated in patients with BPF as a conduit for providing adequate gas exchange at lower mean ventilation pressures⁹. Various HFV approaches including high frequency jet ventilation (HFJV) and high frequency oscillatory ventilation (HFOV) have been proposed and utilized. HFJV employs high gas pressures provided through a small-bore cannula through the endotracheal tube. The small tidal volumes averaging 2 to 5 mL/kg provided at high frequencies ranging from 100 to 200 breaths per minute allows these benefits but also presents difficulties in gas warming and humidification. HFJV has been evaluated in case reports or case series of BPF. In general, HFJV may only be of benefit if the peak airway pressure is reduced with its use¹⁰ (Figure 1). HFOV provides small gas volumes under constant mean airway pressures. Benefits of HFOV include active expiration, decreasing air trapping risks. HFOV, however, requires relatively high mean airway pressures (through auto-PEEP) and its successes have mainly been described in neonates. The successful use of a combination of ILV and HFOV has also been described¹¹.

Intermittent inspiratory chest tube occlusion is another means by which a BPF can be managed. During inspiration, the chest tube is pressured from the ventilator thereby creating a brief pneumothorax and allowing other areas of the lung to be inflated¹² (Figure 2). The success of this technique has been described in case reports or small case series. However, special equipment is needed to be able to pressure the chest tube(s). Consequently, this method has not achieved widespread popularity.

References

- Mwandumba HC, Beeching NJ. Pyogenic lung infections: factors for predicting clinical outcome of lung abscess and thoracic empyema. *Curr Opin Pulm Med* 2000;6:234-9.
- Heffner JE, ed. *Empyema*. New York: McGraw-Hill; 2003.
- Lois M, Noppen M. Bronchopleural fistulas: an overview of the problem with special focus on endoscopic management. *Chest* 2005;128:3955-65.
- Pierson DJ, ed. *Barotrauma and Bronchopleural Fistula*. 2nd ed. New York: McGraw-Hill; 2006.
- Weiss SJ, Ochroch EA, eds. *Thoracic Anesthesia*. New York: McGraw-Hill; 2008.
- Shekar K, Foot CL, Feiser JF. Independent lung ventilation in the intensive care unit: desperate measure or viable treatment option? *Crit Care Resusc* 2008;10:144-8.
- Cheatham ML, Promes JT. Independent lung ventilation in the management of traumatic bronchopleural fistula. *Am Surg* 2006;72:530-3.
- Anantham D, Jagadesan R, Tiew PE. Clinical review. Independent lung ventilation in critical care. *Crit Care* 2005;9:594-600.
- Ten IS, Anderson MR. Is high-frequency ventilation more beneficial than low-tidal volume conventional ventilation? *Respir Care Clin N Am* 2006;12:437-51.
- Albelda SM, Hansen-Flaschen JH, Taylor E, et al. Evaluation of high-frequency jet ventilation in patients with bronchopleural fistulas by quantitation of the airleak. *Anesthesiology* 1985;63:551-4.
- Ichinose M, Sakai H, Miyazaki I, et al. Independent lung ventilation combined with HFOV for a patient suffering from tracheo-gastric roll fistula. *J Anesth* 2008;22:282-5.
- Blanch PB, Koens JC, Jr., Layon AJ. A new device that allows synchronous intermittent inspiratory chest tube occlusion with any mechanical ventilator. *Chest* 1990;97:1426-30.