

3-24-2012

Transfusion-Related Acute Lung Injury during Liver Transplant: Case Report

Nathanael Slater

University of Massachusetts Medical School

Nicholas C. Watson

University of Massachusetts Medical School

Follow this and additional works at: https://escholarship.umassmed.edu/anesthesiology_pubs



Part of the [Anesthesiology Commons](#)

Repository Citation

Slater, Nathanael and Watson, Nicholas C., "Transfusion-Related Acute Lung Injury during Liver Transplant: Case Report" (2012).
Anesthesiology and Perioperative Medicine Publications. 117.

https://escholarship.umassmed.edu/anesthesiology_pubs/117

This material is brought to you by eScholarship@UMMS. It has been accepted for inclusion in Anesthesiology and Perioperative Medicine Publications by an authorized administrator of eScholarship@UMMS. For more information, please contact Lisa.Palmer@umassmed.edu.

Transfusion-related Acute Lung Injury During Liver Transplant: Case Report

Nathanael A. Slater D.O., Nicholas C. Watson M.D.
Department of Anesthesia, University of Massachusetts Medical School, Worcester MA

Introduction

Transfusion-related acute lung injury (TRALI) is defined as noncardiogenic pulmonary edema temporally related to the transfusion of blood products.^{1,2} We present a patient who, while undergoing orthotopic liver transplantation, developed acute pulmonary edema within minutes of administration of fresh frozen plasma (FFP).

Intraoperative Course

A 71 year-old female presented for orthotopic liver transplantation. She was brought to the operating room and underwent uneventful induction of general anesthesia, vascular access placement, and tracheal intubation. The operative field was noted to have continual bleeding and blood products were administered to improve hemostasis. Within minutes of administration of FFP, copious amounts of pale yellow, frothy fluid filled the endotracheal tube and the patient's oxygen saturation dropped from 100% to 90%. The patient was placed on 100% FIO₂, intermittent suctioning removed 1L of fluid, and IV furosemide was given. Hemodynamics and oxygenation stabilized, the operation was completed without further difficulty, including transfusion of additional blood products.

SICU Course

The patient arrived in the SICU on 100% FIO₂ and 10 of PEEP. Vasopressin and norepinephrine were being administered due to persistent hypotension, likely secondary to large intravascular volume shifts during the procedure (approximately 7 liters of ascites were drained from her abdomen). Over the next 36 hours, the goal of therapy shifted from volume resuscitation to diuresis and weaning from mechanical ventilation. By the end of post-op day #2 the patient was on 40% FIO₂ and spontaneously ventilating with CPAP. Prolonged encephalopathy prevented successful extubation and the patient had a tracheostomy placed post-op day #6. She was successfully liberated from mechanical ventilation the next day. The remainder of her hospital course was uneventful and she was discharged to rehab three weeks later. As of this past January, on follow-up in transplant clinic, she is doing well, has a healthy appetite, and is able to participate in the day to day activities of her family life. She has had multiple type and screens drawn and her antibody screen remains persistently negative.

TRALI: Differential diagnosis

The differential diagnosis of TRALI includes transfusion-associated circulatory overload (TACO), left ventricular failure, exacerbation or progression of ALI from another cause, ARDS, sepsis, trauma, smoke inhalation, aspiration pneumonitis or pneumonia. The patient had no prior ALI, had no active infections, and had not been subject to trauma. Intraoperative TEE demonstrated normal function of the left and right ventricles. TACO was ruled out on the basis of preoperative hypovolemia, removal of 7 L of ascites, a normal TEE, no changes on EKG, and a temporal relationship with the transfusion of 2 units of FFP.

TRALI: Figure 1. Intraoperative Diagnosis

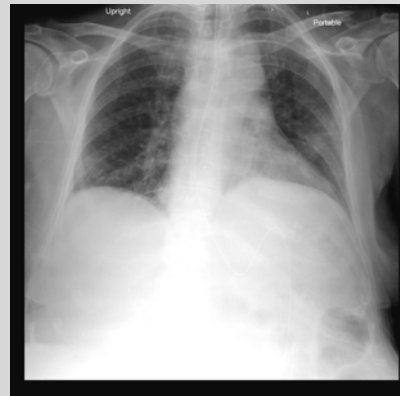

At left: One of two containers of pulmonary edema suctioned from the patient's ETT.

At right: Sequential ABG's obtained intraoperatively and immediately postop. Induction was at 5:45 AM, transfusion of FFP occurred at 6:45AM. FIO₂ at induction was 40% with 5 of PEEP on volume cycled ventilation. The second ABG is at 06:51 at which time copious amounts of fluid were being removed from the ETT via suction. FIO₂ was 100%, PEEP 10. Post-operatively, almost 12 hours later, ventilation, oxygenation, and respiratory mechanics had improved significantly. The patient was on 60% FIO₂ with 5 of PEEP.

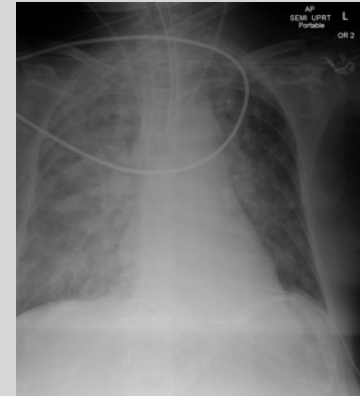
ABG	Post-Induction	Onset of TRALI	Post-op
FIO ₂	40%	100%	60%
pH	7.32	7.11	7.36
PaCO ₂	38	59	36
PaO ₂	138	129	108
HCO ₃	19.2	16.2	20
O ₂ sat%	99	98	100

TRALI: Figure 2. Imaging



At left: Preop CXR demonstrating mild lower lobe collapse, but otherwise clear lungs.

At right: CXR immediately post-op, showing diffuse bilateral infiltrates consistent with pulmonary edema



TRALI: Definition and Current Concepts

Brittingham reported the first link between symptoms of ALI, transfusion and leukoagglutinins in 1957. The term TRALI was coined by Popovsky in 1983 after describing a series of cases of ALI in association with leukoagglutinin in the blood component¹. Partially because of vigilance in preventing the spread of viral illness, TRALI has, according to the FDA, become the leading cause of morbidity and mortality associated with blood transfusion. In 2005, the National Heart, Lung, and Blood Institute convened a panel to provide a clinically useful definition which is, "new ALI occurring during or within 6 hours after a transfusion, in patients with or without risk factors for ALI other than transfusion."¹ There are two theories as to how injury to the lung occurs in relation to transfusion. One is the "Two Hit Hypothesis" which involves immune priming and the introduction of a TRALI producing agent³. Priming sensitizes the vascular endothelium to a trigger which may be the same agent at a higher dose or another agent entirely. The trigger in TRALI appears to be lipids from stored blood². The "Antibody Hypothesis" focuses on donor derived anti-leukocyte antibodies that trigger increased vascular permeability in the lung. HLA class I and II from female, multiparous donors have been implicated in cases of TRALI¹. The components with the highest risk of producing TRALI are FFP and platelets¹. Treatment is supportive, with sequelae resolving within 96 hours of onset. The incidence of TRALI in liver transplant patients is 1.3% and was found to be associated with plasma-containing products only (FFP, platelets)⁴. Rate of infection was directly related to PRBC administration in a dose dependant manner⁴. Given the complications related to transfusion, it is prudent to minimize transfusion of blood products as much as possible⁵.

References

1. Trulzji DJ. Transfusion Related Acute Lung Injury: Current Concepts for the Clinician. Anesth Analg 2009; 108: 770-776
2. Looney MR, Gropper MA, Matthay MA. Transfusion Related Acute Lung Injury: A Review. Chest 2004; 126: 249-258
3. Gilliss BM, Looney MR. Experimental Models of TRALI. Transfus Med Rev 2011; 25(1): 1-11
4. Benson AB, Burton AR. Differential effects of plasma and red blood cell transfusions on acute lung injury and infection risk following liver transplantation. Liver Transpl. 2011. 17(2):149-58
5. Ozier Y, Tsou MY. Changing trends in transfusion practice in liver transplantation. Cur Opin Organ Transplant. 2008. 13(3):304-9

Abbreviations

ABG: arterial blood gas	FDA: Food and Drug Administration	TEE: transesophageal echocardiogram
ALI: acute lung injury	FFP: fresh frozen plasma	TACO: transfusion-associated circulatory overload
ARDS: acute respiratory distress syndrome	FIO ₂ : fraction of inspired oxygen	
CPAP: continuous positive airway pressure	PEEP: positive end expiratory pressure	
CXR: chest x-ray		
ETT: endotracheal tube		