

NEUROLOGICAL BULLETIN

FEATURING ARTICLES BY TRAINEES IN NEUROLOGY & NEUROSCIENCE

Chemotherapy-Induced Myelopathy

Wissam Deeb

Department of Neurology
University of Massachusetts Medical Center, Worcester, MA

A 56-year-old man with a diagnosis of epidural compression of the thoracic spinal cord (T₆ - T₈) due to Burkitt's lymphoma had surgical decompression with persistent myelopathy. He presented with worsened lower extremity numbness and weakness after the fifth cycle of systemic cytarabine and intrathecal methotrexate. Examination disclosed a spastic ataxic paraparesis, with unremarkable serum (including vitamin B₁₂, TSH, Cu⁺⁺, vitamin E, syphilis IgG) and CSF values. MRI of the spinal cord showed T2 hyperintensity of the posterolateral columns, characteristic of chemotherapy-induced myelopathy.¹

Myelopathy following chemotherapy is a rare but devastating complication (mostly from methotrexate and cytarabine).^{1,4,5} The latency to onset of symptoms can be delayed, which include back pain and a rapidly progressive paraparesis, sensory level and bladder/bowel involvement.^{2,3,5} MRI scans show focal cord swelling in the posterior and lateral columns.¹ It is a diagnosis of exclusion and carries a poor prognosis.⁵

References

1. Saito F, Hatano T, Hori M, et al. Lateral and dorsal column hyperintensity on magnetic resonance imaging in a patient with myelopathy associated with intrathecal chemotherapy. *Case Rep Neurol* 2013;5:110-115, <http://dx.doi.org/10.1159/000351848>
2. López-Andreu JA, Ferris J, Verdeguer A, Esquembre C, Castel V. Myelopathy after intrathecal chemotherapy: a case report with unique magnetic resonance imaging changes. *Cancer* 1995;75:1216-1217.
3. McLean DR, Clink HM, Ernst P, et al. Myelopathy after intrathecal chemotherapy. A case report with unique magnetic resonance imaging changes. *Cancer* 1994;73:3037-3040.
4. Ackermann R, Semmler A, Maurer GD, et al. Methotrexate-induced myelopathy responsive to substitution of multiple folate metabolites. *J Neurooncol* 2010;97:425-427, <http://dx.doi.org/10.1007/s11060-009-0028-9>
5. Dropcho EJ. Neurotoxicity of cancer chemotherapy. *Semin Neurol* 2010;30:273-286, <http://dx.doi.org/10.1055/s-0030-1255217>

Correspondence to Wissam Deeb: wissam.deeb@umassmemorial.org

Keywords: chemotherapy, myelopathy, cytarabine, methotrexate, spinal MRI

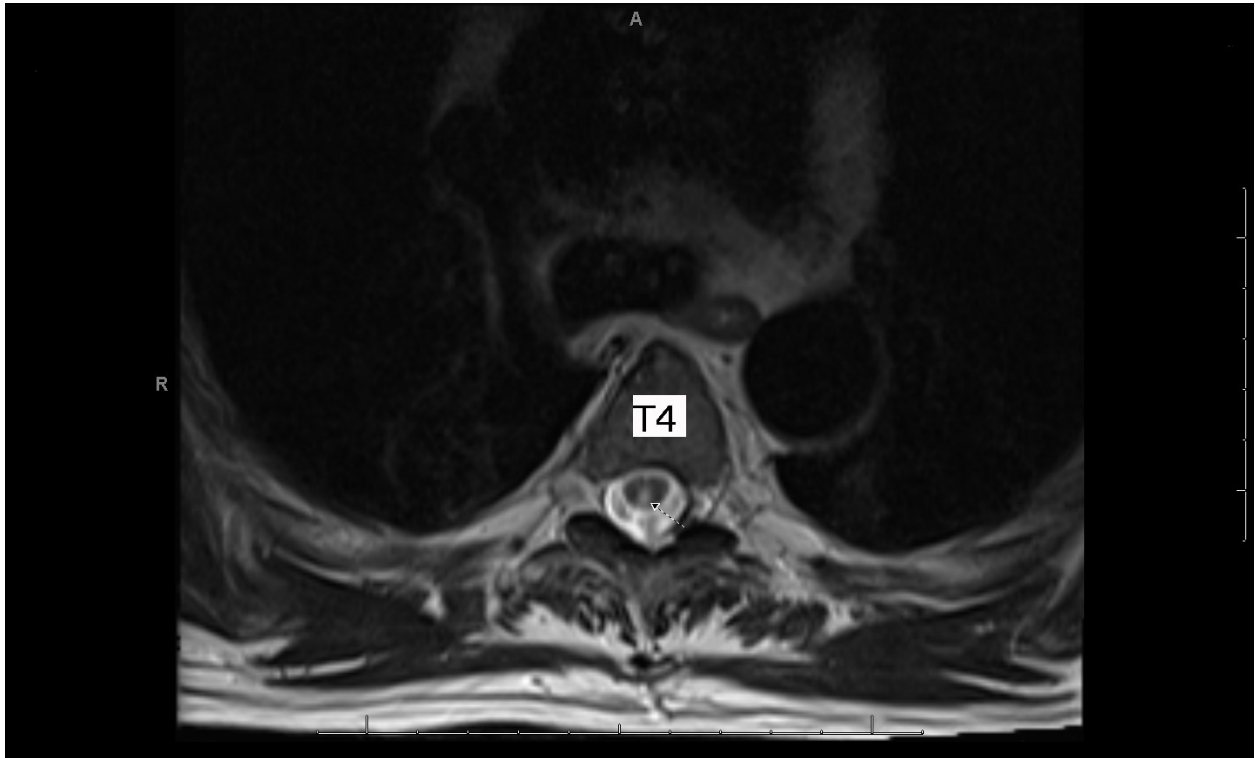


Figure 1: Axial T2 image of the thoracic spine at the T4 level showing hyperintensity at the level of the posterior columns (arrow).

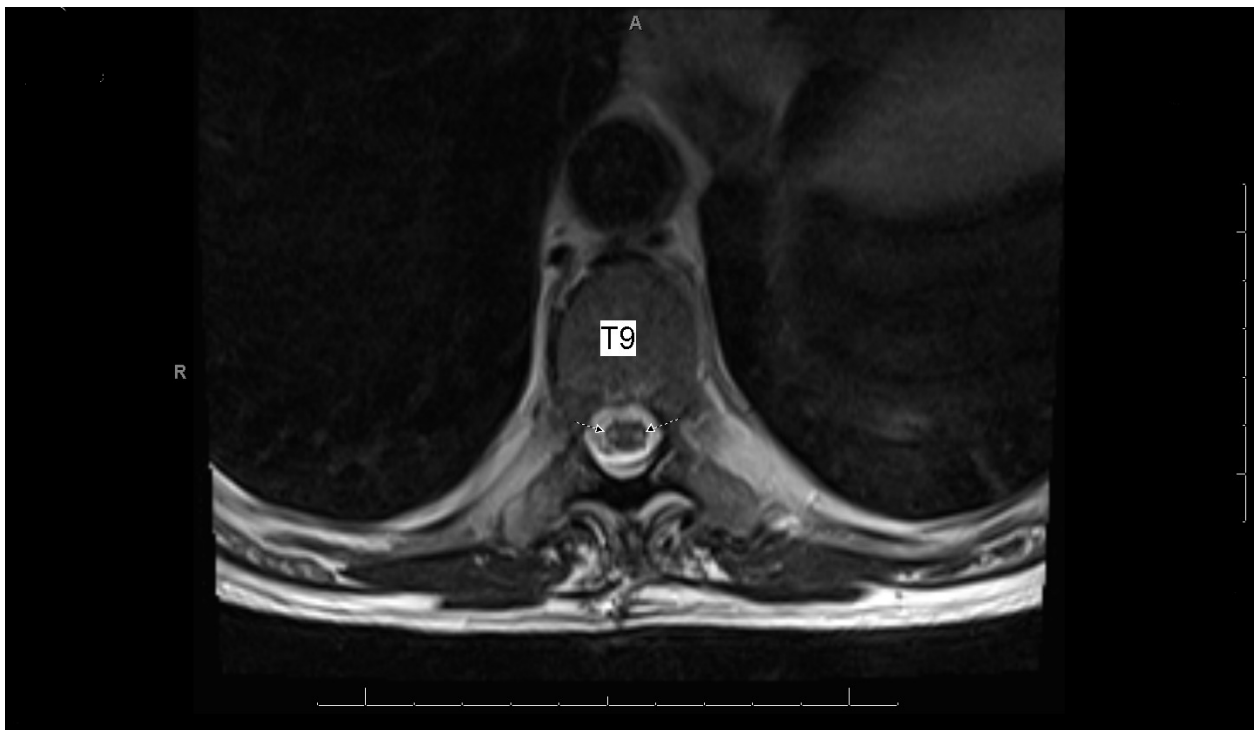


Figure 2: Axial T2 image of the thoracic spine at the T9 level showing hyperintensity at the level of the lateral columns (arrows).

Disclosure: the author reports no conflicts of interest.

All content in Neurological Bulletin, unless otherwise noted, is licensed under a Creative Commons Attribution-Noncommercial-Share Alike License <http://creativecommons.org/licenses/by-nc-sa/3.0/> (ISSN 1942-4043)

Disclosure: the authors report no conflicts of interest.

All content in Neurological Bulletin, unless otherwise noted, is licensed under a Creative Commons Attribution-Noncommercial-Share Alike License <http://creativecommons.org/licenses/by-nc-sa/3.0/> (ISSN 1942-4043)