

NEUROLOGICAL BULLETIN

FEATURING ARTICLES BY TRAINEES IN NEUROLOGY & NEUROSCIENCE

Acute Calcific Longus Colli Tendinitis: An Underdiagnosed Cause of Neck Pain and Dysphagia

Swetha Ade, Ajay M. Tunguturi, and Ann Mitchell

Department of Neurology
University of Massachusetts Medical Center, Worcester, MA

Introduction

Etiologies for neck pain are multiple but those associated with dysphagia remain limited to retropharyngeal abscess, soft tissue swellings, trauma, oro-pharyngeal neoplasms and acute calcific longus colli tendinitis. Acute calcific longus colli tendinitis is an inflammation of the longus colli tendon that manifests with acute onset of neck pain that is often associated with torticollis and when more advanced, with dysphagia or odynophagia. We present a 39 year old woman who developed acute onset of neck pain that over the next few days progressed to involve dysphagia. Multiple imaging studies were performed that eventually supported the diagnosis of acute calcific longus colli tendinitis. We would like to raise awareness of acute calcific longus colli tendinitis as an often under-diagnosed cause of acute neck pain.

Case Report

The patient is a 39 year old hairdresser, with a history of occasional neck and proximal

shoulder pain. One morning she woke up with neck pain that was much worse than her usual neck pain. There was no known antecedent trauma, unusual physical exertion or strain to the neck. The pain continued to worsen the next day, when she also noticed mild restriction of her neck movements. She denied any fever, nausea or vomiting. The neck pain continued to gradually worsen. On day three she developed dysphagia for both solids and liquids. Neurological examination revealed increased cervical muscle tone and tenderness to light palpation all along the cervical spine. There were no visible signs of inflammation on routine oro-pharyngeal examination. There were no signs of meningismus. Laboratory tests revealed elevated ESR of 75 and CRP of 16.6, suggestive of acute inflammation. CBC was within normal limits. The absence of fever and meningismus, along with the normal CBC made a diagnosis of meningitis less likely, but still theoretically possible. With the patient's neck pain and stiffness worsening, an MRI of the neck with contrast was performed to look for pre-vertebral or epidural abscess. Imaging revealed bilateral longus colli muscle

Correspondence to Ajay Tunguturi: ajay.tunguturi@umassmemorial.org

Keywords: longus colli tendinitis, dysphagia, retropharyngeal abscess, occipital headache, torticollis

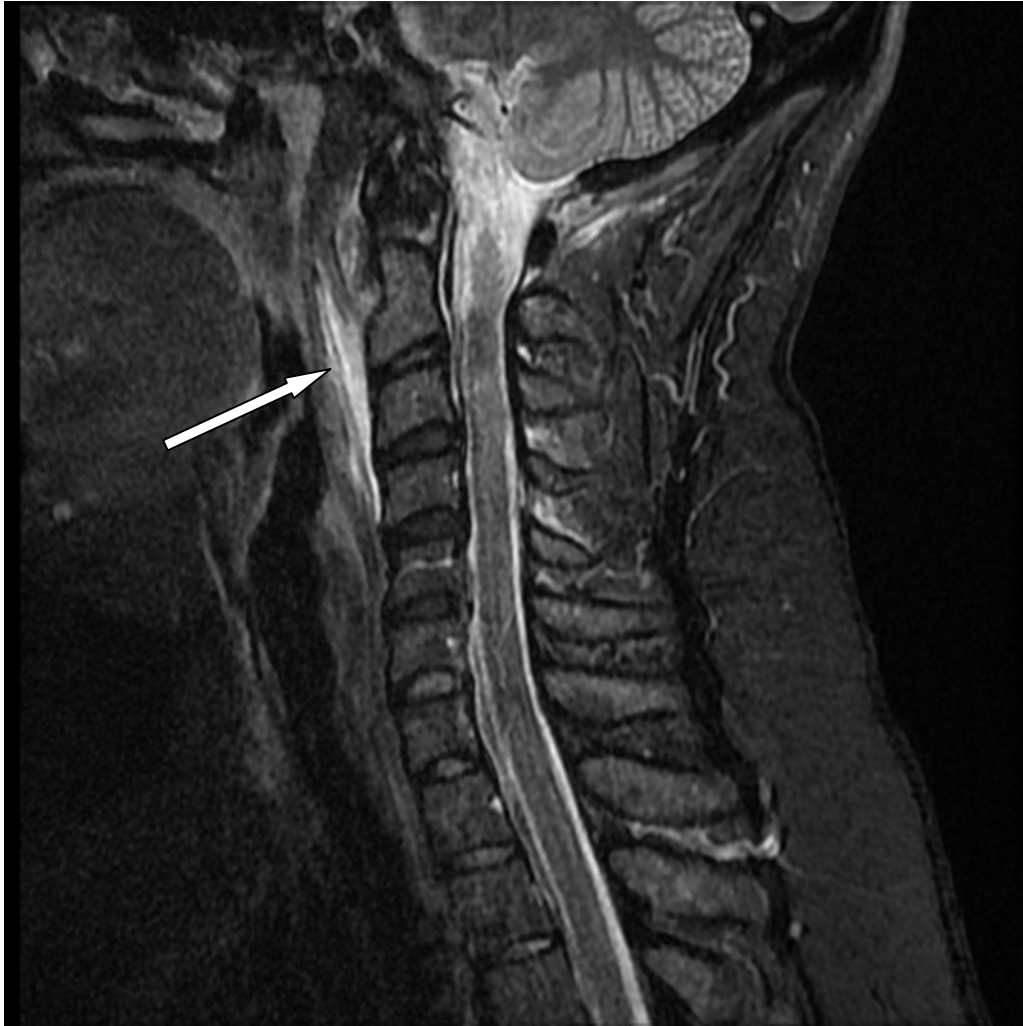


Figure 1: Sagittal STIR sequence image demonstrates inflammation of the longus colli tendon (arrow).

edema with ill defined contrast enhancement and pre-vertebral soft tissue swelling (Figure 1). There was a non-circumscribed fluid level extending from C1 to C4 level (Figure 2), and reversal of the cervical lordosis. Pre-vertebral abscess was considered in the differential, but there were no other signs of acute infection. Before proceeding with any invasive procedures, such as fine needle aspiration cytology, CT scan of the neck was performed to confirm the presence of calcifications in the longus colli tendon. The CT of the neck was consistent with thickening of the pre-vertebral soft tissues and longus colli

muscle from the level of the craniovertebral junction down to C5 level. Focal ring like calcifications (Figure 3) within the longus colli muscle/tendon were also noted. The absence of other signs and symptoms of infection, along with the presence of the elevated ESR and the calcified deposits on the CT scan, confirmed the diagnosis of acute calcific longus colli tendinitis. The patient was treated with non-steroidal anti-inflammatory drugs, and she reported resolution of symptoms within two weeks of initiating treatment. No follow up imaging was performed. The patient was thus spared the need for in-

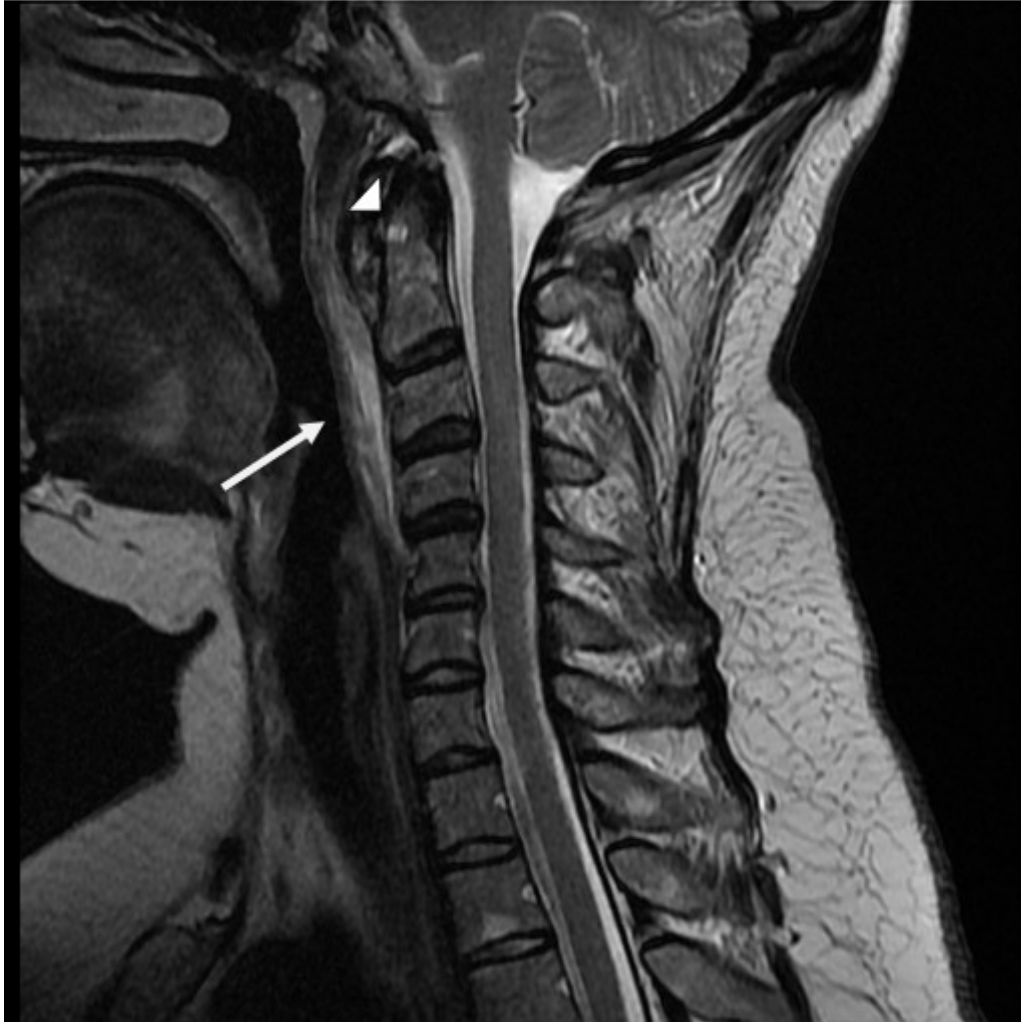

Figure 2: Sagittal T2-weighted FR FSE sequence image demonstrates fluid collection (arrow) within the pre-vertebral soft tissues, with calcification (arrow head) in the proximal fibers of the longus colli tendon.

vasive studies in the retropharyngeal space.

Discussion

This case highlights the importance of considering some of the less common etiologies for neck pain, and more specifically, acute calcific longus colli tendinitis. Awareness of this condition might obviate the need for potentially life threatening diagnostic interventions and unnecessary treatments. The longus colli muscle is situated in front of the vertebral column between the atlas and the

third thoracic vertebral body (Figure 4). These bilateral muscles primarily help in the flexion of the head and neck. Acute calcific longus colli tendinitis is thought of as a rare disease.^{1,2} Recent epidemiological studies by Horowitz et al have shown that it occurs with an age-matched incidence of 1.31 per 100,000 person-years.³ It typically presents with pain in the neck that is followed by stiffness in the neck and odynophagia;^{4,5} patients may also experience a referred pain to the occipital area.¹ Although this condition appears to be acute in onset, a case se-

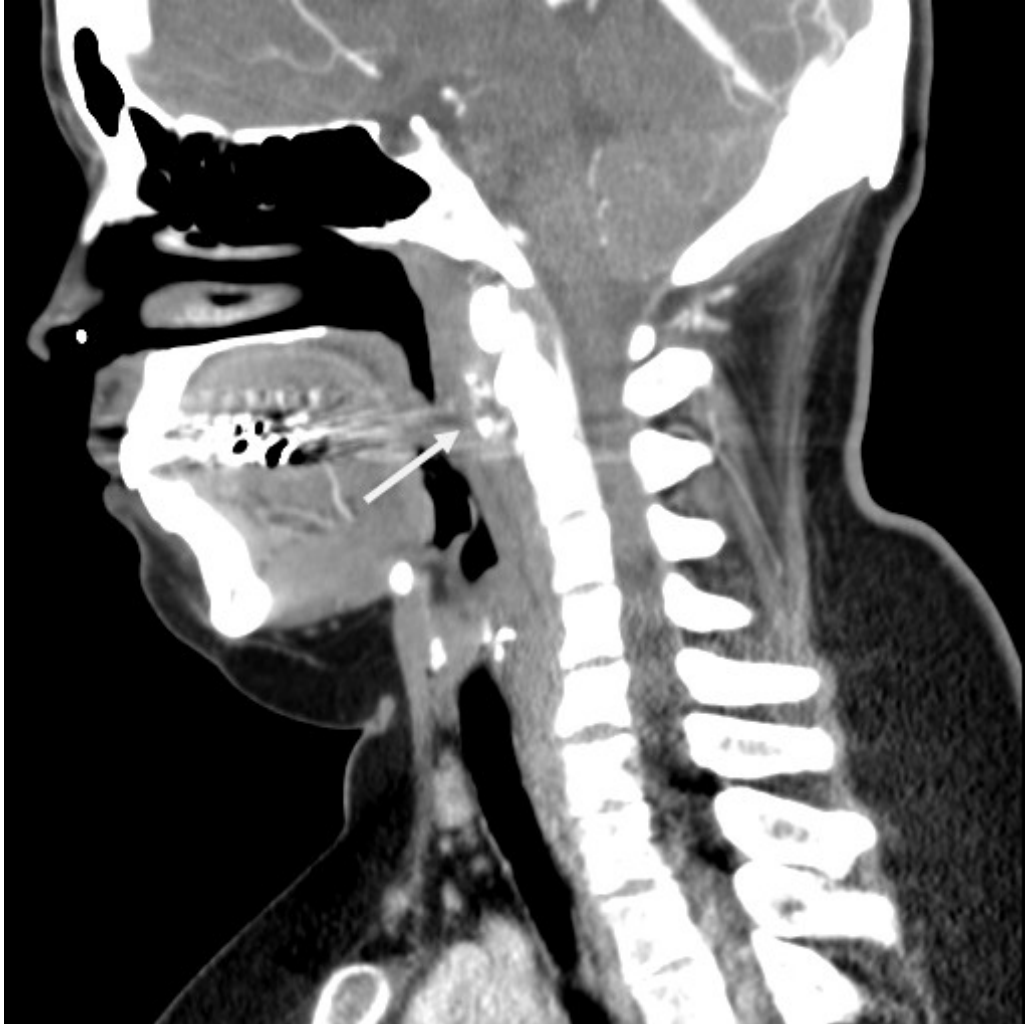


Figure 3: Sagittal CT neck demonstrates focal ring like calcifications (arrow) within the longus colli muscle/tendon.

ries by Bernstein reported that sometimes there might have been prior neck trauma by whiplash or flu like symptoms occurring a week prior to the symptom onset.⁶ A high degree of suspicion and a careful physical examination are required to rule out meningitis and/or other CNS infections, such as epidural abscess. In our case, the patient did not have any signs or symptoms of infection. Laboratory studies are usually within normal limits, although an elevated ESR and mild leukocytosis can be seen.^{5,6} As found in our patient, the key radiographic findings of retropharyngeal calcific tendinitis include pre-

vertebral soft tissue swelling, and amorphous calcification anterior to C1–C2.⁸⁻¹⁰ Diffuse pre-vertebral soft tissue thickening typically extends from C1 to C4.⁵ The soft tissue thickening represents either a discrete effusion or diffuse edema, which can be differentiated on CT or MRI.^{7,11} As in our case, the fluid can easily spread through the pre-vertebral space and localize within the muscle, and thereby expand the retropharyngeal space and potentially be confused with an abscess collection in the retropharyngeal space.¹⁰ The lack of enhancement surrounding the effusion is helpful in differentiating a

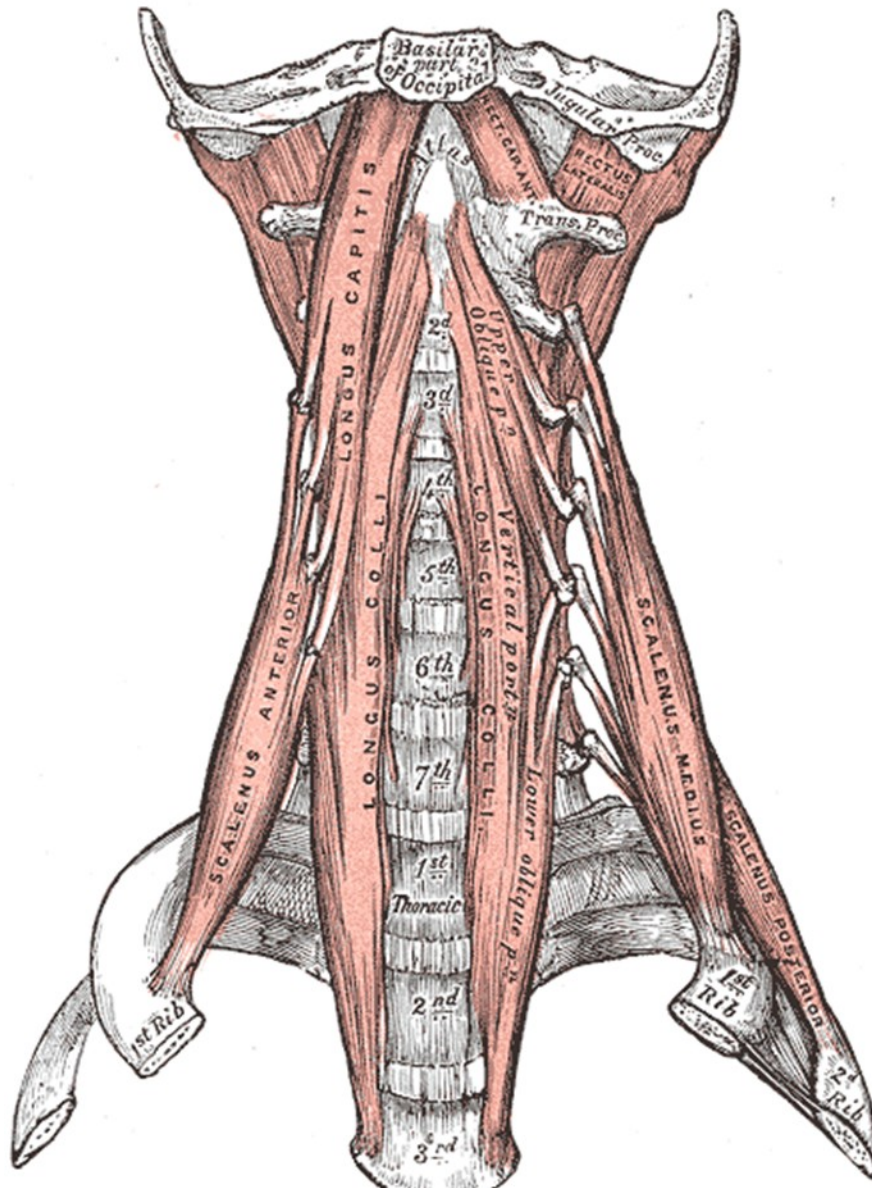


Figure 4: Anatomical Illustration of Longus Colli Muscle. Reproduced from *Anatomy of the Human Body*, 20th ed.¹³

reactive effusion from an abscess.¹² Treatment with a short course of non-steroidal anti-inflammatory medication and avoidance of aggravating neck movements help to alleviate the symptoms. A short course of steroids might be considered for refractory cases.⁷ Acute calcific longus colli tendinitis is generally a self-limiting condition that tends to resolve after 1–3 weeks.^{4,7} Increased phy-

sician awareness of acute calcific longus colli tendinitis would permit its more timely diagnosis and appropriate treatment and avoid unnecessary invasive interventions or other unwarranted treatments.

References

1. Harnier S, Kuhn J, Harzheim A, Bewermeyer H, Limmroth V. Retropharyngeal tendinitis: a rare differential diagnosis of severe headaches and neck pain. *Headache* 2008;48:158-161, <http://dx.doi.org/10.1111/j.1526-4610.2007.00915.x>
2. Zibis AH, Giannis D, Malizos KN, Kitsioulis P, Arvanitis DL. Acute calcific tendinitis of the longus colli muscle: case report and review of the literature. *Eur Spine J* 2013;22:S434-S438, <http://dx.doi.org/10.1007/s00586-012-2584-5>
3. Horowitz G, Ben-Ari O, Brenner A, Fliss DM, Wasserzug O. Incidence of retropharyngeal calcific tendinitis (longus colli tendinitis) in the general population. *Otolaryngol Head Neck Surg* 2013;148:955-958, <http://dx.doi.org/10.1177/0194599813482289>
4. Ring D, Vaccaro AR, Scuderi G, Pathria MN, Garfin SR. Acute calcific retropharyngeal tendinitis. Clinical presentation and pathological characterization. *J Bone Joint Surg Am* 1994;76:1636-1642.
5. Fahlgren H. Retropharyngeal tendinitis. *Cephalalgia* 1986;6:169-174, <http://dx.doi.org/10.1046/j.1468-2982.1986.0603169.x>
6. Bernstein SA. Acute cervical pain associated with soft-tissue calcium deposition anterior to the interspace of the first and second cervical vertebrae. *J Bone Joint Surg Am* 1975;57:426-428.
7. Park R, Halpert DE, Baer A, Kunar D, Holt PA. Retropharyngeal calcific tendinitis: case report and review of the literature. *Semin Arthritis Rheum* 2010;39:504-509, <http://dx.doi.org/10.1016/j.semarthrit.2009.04.002>
8. Eastwood JD, Hudgins PA, Malone D. Retropharyngeal effusion in acute calcific prevertebral tendinitis: diagnosis with CT and MR imaging. *AJNR AmJ Neuroradiol* 1998;19:1789-1792.
9. Chung T, Rebello R, Gooden EA. Retropharyngeal calcific tendinitis: case report and review of literature. *Emerg Radiol* 2005;11:375-380.
10. Offiah CE and Hall E. Acute calcific tendinitis of the longus colli muscle: spectrum of CT appearances and anatomical correlation. *Br J Radiol* 2009;82: e117-e121, <http://dx.doi.org/10.1259/bjr/19797697>
11. Artenian DJ, Lipman JK, Scidmore GK, Brant-Zawadzki M. Acute neck pain due to tendonitis of the longus colli: CT and MRI findings. *Neuroradiology* 1989;31:166-169.
12. Hoang JK, Branstetter BF 4th, Eastwood JD, Glastonbury CM. Multiplanar CT and MRI of collections in the retropharyngeal space: is it an abscess? *AJR Am J Roentgenol* 2011;196:W426-W432, <http://dx.doi.org/10.2214/AJR.10.5116>
13. Gray H. Anatomy of the Human Body, 20th ed. In: Bartleby.com [online]. Available at: <http://www.bartleby.com/107/illus387.html>

Disclosure: the authors report no conflicts of interest.

All content in Neurological Bulletin, unless otherwise noted, is licensed under a Creative Commons Attribution-Noncommercial-Share Alike License <http://creativecommons.org/licenses/by-nc-sa/3.0/> (ISSN 1942-4043)