

NEUROLOGICAL BULLETIN

FEATURING ARTICLES BY TRAINEES IN NEUROLOGY & NEUROSCIENCE

Alexander Disease: Demonstration on Neuroimaging

Nilika Shah Singhal and Audrey Foster-Barber

Division of Child Neurology
University of California, San Francisco, San Francisco, CA

A 4-year-old boy with developmental delay presented after a seizure. Head circumference was 50th percentile; height and weight were 10th. CT and MRI demonstrated characteristic findings of Alexander disease (see figures).

Alexander disease^{1,2} is one of the heterogeneous group of diseases called leukodystrophies. Patients typically present with megalencephaly, psychomotor regression, ataxia, and seizure; adults may present with bulbar symptoms. It is most often caused by de novo mutations in the GFAP gene; toxic aggregates likely contribute to the classic histopathology of Rosenthal fibers. Imaging findings^{3,4} may not correlate with disease severity, leading to challenges in counseling patients.

References

1. Messing A, Daniels CM, Hagemann TL. Strategies for treatment in Alexander disease. *Neurotherapeutics* 2010;7:507-515.
2. Sawaisi Y. Review of Alexander disease: beyond the classical concept of leukodystrophy. *Brain Dev* 2009;31:493-498, <http://dx.doi.org/10.1016/j.braindev.2009.03.006>
3. van der Knaap MS, Naidu S, Breiter SN, et al. Alexander disease: diagnosis with MR imaging. *AJNR Am J Neuroradiol* 2001;22:541-552.
4. Bizzi A, Castelli G, Bugiani M, et al. Classification of childhood white matter disorders using proton MR spectroscopic imaging. *AJNR Am J Neuroradiol* 2008;29:1270-1275, <http://dx.doi.org/10.3174/ajnr.A1106>

Disclosure: the authors report no conflicts of interest.

All content in Neurological Bulletin, unless otherwise noted, is licensed under a Creative Commons Attribution-Noncommercial-Share Alike License <http://creativecommons.org/licenses/by-nc-sa/3.0/> (ISSN 1942-4043)

Correspondence to Nilika Shah Singhal: singhaln@neuropeds.ucsf.edu

Keywords: leukodystrophy, Alexander, developmental delay, GFAP, Rosenthal fibers

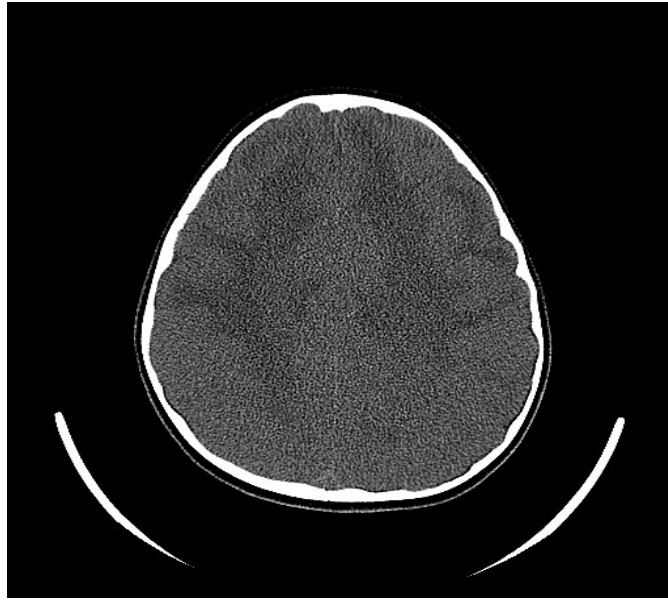

Figure 1: Noncontrast head CT exhibiting bilateral symmetric diffuse deep white matter hypodensities, more marked in the frontal lobes.

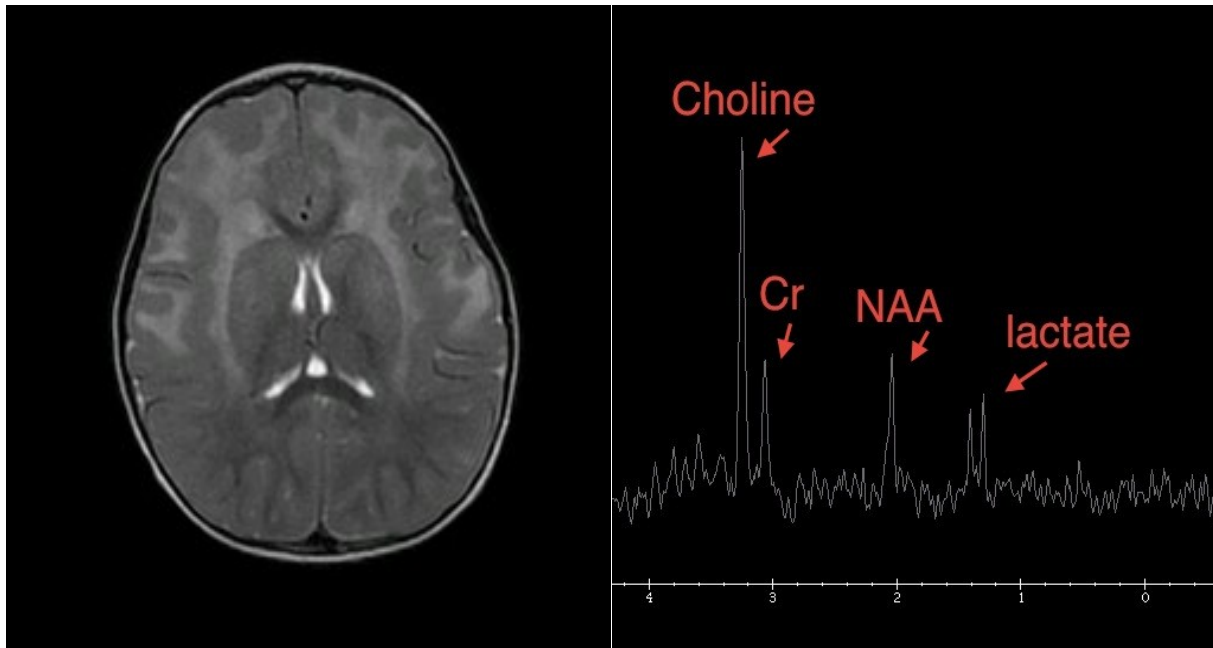


Figure 2: T2 weighted MRI exhibiting diffuse predominantly frontal lobe subcortical white matter T2 prolongation with swelling and edema involving the lentiform nuclei. MR spectroscopy demonstrated elevated choline peak, decreased NAA peak, elevated lactate within the frontal white matter with increased myoinositol on short echo white matter spectra.