

NEUROLOGICAL BULLETIN

FEATURING ARTICLES BY TRAINEES IN NEUROLOGY & NEUROSCIENCE

On Catatonia and Dementia: A Case Report

Jordan Eisenstock

Department of Neurology
University of Massachusetts Memorial Medical Center, Worcester, MA

The many pitfalls in the accurate diagnosis of dementias are well documented. While definitive diagnosis remains the goal, the limits of clinicopathologic knowledge and current technology oftentimes preclude firm decisions on a specific diagnosis, treatment and plans. This is particularly pertinent in those cases where the lines between neurology and psychiatry become somewhat blurred. In this report, I present the case of a patient with probable catatonic depression masquerading initially as frontotemporal dementia. Included is a brief discussion outlining our current knowledge about catatonia: its pertinent signs and symptoms for accurate diagnosis, its possible pathophysiologic mechanisms, and its relationship to dementia.

Case Report

The patient is a 56 year old right-handed gentleman who worked for several years in a supervisory role with the city department of public works and presented to our inpatient psychiatry unit for one month of worsening depression. Neurovegetative symptoms included insomnia, poor appetite and difficulty concentrating. There was a potential precipitating event as the patient's mother had re-

cently passed away about two months prior to admission.

With the exception of one prior psychiatric admission about 20 years earlier, also for worsening depression in the context of a family issue, the patient had never consistently required psychiatric attention. About two years prior to this admission he had seen an outpatient psychiatrist for a couple of months secondary to anxiety and panic symptoms and was started on an SSRI and a benzodiazepine. At the time of admission his only medications were HCTZ/Triamterene for hypertension and Lumigan drops for glaucoma. He had been off of all neuropsychiatric medications for at least one year. His family history was only notable for question of late-onset dementia in the patient's mother.

The neurology service came to be involved with this patient after the admitting examination by the psychiatry resident noted subtle perseveration on testing of extraocular movements, brisk reflexes and difficulty changing set despite a MMSE of 30/30. An initial neurology consultation yielded a diagnosis of Cognitive Symptoms Due to Depression and

Correspondence to Jordan Eisenstock: jordan.eisenstock@umassmemorial.org

Keywords: catatonia, electroconvulsive therapy, lorazepam, frontotemporal dementia, glutamate, GABA

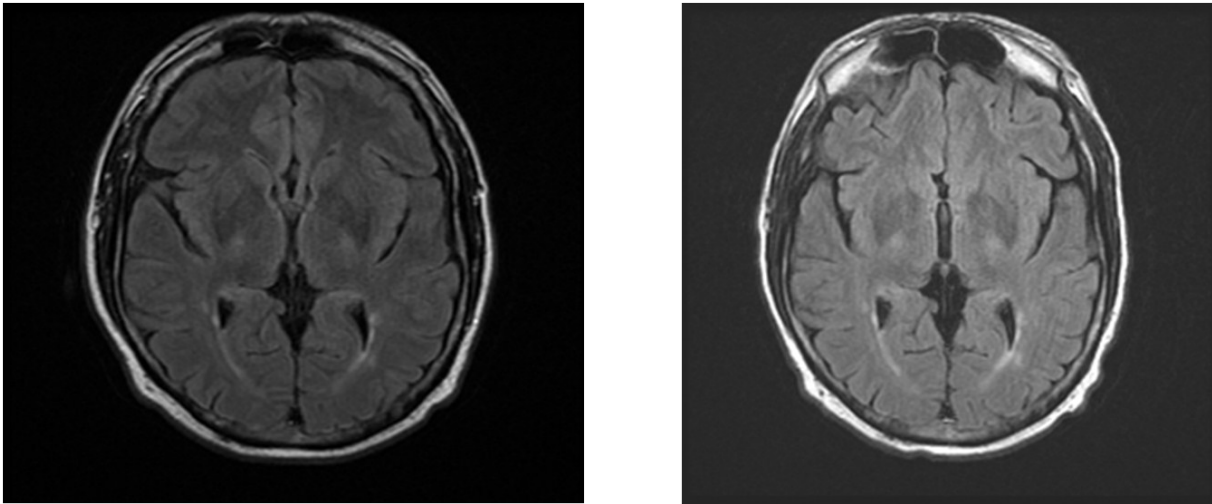


Figure 1: Left image dated April 2006. Right image dated September 2007.

the brisk reflexes were explained by cervical pathology on MRI. The inpatient psychiatry team resumed the patient's SSRI and added an atypical antipsychotic to the regimen and after two weeks the patient was discharged to his home.

After continued deterioration despite compliance with medications the patient returned to the psychiatric emergency room a couple of months later. Again he was admitted to the inpatient psychiatry unit and trials of new SSRI's and atypical antipsychotic produced little clinical response. Shortly after discharge from the psychiatry service he was seen in the outpatient neurology clinic for follow-up of the original consultation.

By this time the patient demonstrated minimal verbal output, most responses being a rather stereotypic and hesitant "I don't know" to all variety of questions. His family noted significant balance problems and he had fallen several times at home. In addition to mild rigidity and a grasp reflex, the patient was also noted to have startle myoclonus on examination. Subsequently the patient was

directly admitted to the inpatient neurology service for a rapidly progressive dementia workup. Of significance, the patient's MRI showed minimal nonspecific white matter changes but no atrophy (Figure 1) and the laboratory findings were not suggestive of any underlying neurologic etiology (summarized in Table 1). An EEG in both the awake and asleep states was also normal.

Over the course of the next four months the patient continued to decline, his verbal output decreased and there were few spontaneous movements. The patient was no longer getting out of bed to toilet himself, and he would not voluntarily eat even if the food was delivered to him. Though there was no formal disagreement, the psychiatry service suspected a dementia diagnosis and the neurology service tended toward a psychiatric etiology. Eventually a trial of ECT was ordered but was unfortunately suspended early secondary to presumed increased confusion in the setting of a urinary tract infection. Soon thereafter the patient was sent for a second opinion at another large academic medical center and returned to our outpatient

Table 1: Laboratory Summary

- Basic Metabolic Panel: normal
- Complete Blood Count: normal
- Liver Function Tests: normal
- Fasting Lipid Profile: normal
- Amylase/Lipase: normal
- Porphyrins: normal
- TSH: normal
- B12: normal
- Folate: normal
- CSF: 0 WBC, 0 RBC
- CSF: protein, glucose normal
- CSF: oligoclonal bands absent
- CSF: 14-3-3 negative
- Drugs of Abuse Screen: negative
- Sedimentation Rate: 45 (High, >20)
- HbA1C: normal
- Serum Protein Electrophoresis: normal
- Anti-Ri/Ma/Ta/Yo/Hu: negative
- VDRL/RPR: non-reactive
- Lyme Serum & CSF: unremarkable
- EBV CSF: negative
- Parv B19: negative
- VCA-IgM/IgG: negative
- EBNA-IgG: negative
- Admark Tau/ABeta42: unremarkable

clinic one month later with the opinion of likely frontotemporal dementia. A decision had been made at the other institution to defer further ECT treatments, and the family was advised to explore nursing home placement options. A PET scan at the other institution had apparently demonstrated frontotemporal hypometabolism, which along with the clinical evaluation had precipitated the above diagnosis.

Approximately six months after the first psychiatric hospitalization the patient returned to the inpatient neurology service. On the second evening of admission the patient rather suddenly and unexpectedly shifted from his longstanding stuporous state to a verbally and physically aggressive appearance. Intramuscular lorazepam was prescribed and within minutes the patient not only calmed down but voluntarily proceeded to get out of bed and go to the restroom. Later that evening he seemed to enjoy his dinner and conversed with family for the first time in months. A standing dose of lorazepam was initiated, and a previously suggested diagnosis of a catatonic-like, rather than frontotemporal-like, state was supported.

It is now two and a half years since the pa-

tient's initial presentation on the psychiatric unit. His current medications include memantine, topiramate and citalopram. For a short period of time the patient also required olanzepine secondary to paranoid thoughts about leaving his home; but this medication, along with maintenance lorazepam, has been successfully discontinued over the past several months. Though he has been unable to return to his previous work, his sense of humor has returned, his abnormal gait has resolved and his performance on formal neuropsychological testing has improved. A repeat PET scan was obtained and was normal, likely indicating that his previous scan was secondary to severe refractory depression rather than frontotemporal dementia.

Discussion

This patient's case illustrates many of the important teaching points when considering a diagnosis of catatonia. Most experts agree that catatonia is severely under-diagnosed in the neuropsychiatric community. Theories exist to explain this phenomenon, such as lack of teaching about catatonia in medical school, lack of agreed-upon classifications and guidelines for recognizing catatonia, and a general lack of understanding of the patho-

Table 2: Phenomenology of Catatonia

EXCITEMENT

Hyperkinesia
 Stereotypies [repetitive/ritualistic movements, postures or utterances]
 Mannerisms [gestures that become abnormal with exaggeration]
 Euphoria
 Irritability
 Rigidity
 Autonomic Changes
 Hypertension
 Hyperpyrexia
 Diaphoresis
 Tachycardia
 Tachypnea
 Mydriasis

STUPOR

Motor Behaviors
 Catalepsy
 Rigidity
 Waxy Flexibility [maintained immobile posture]
 Posturing
 Psychological Pillow [continued elevation of head as if supported by a pillow]
 Grimacing
 Negativism
 Gegenhalten
 Mutism
 Ambitendency [tendency to act in opposite ways from expected]
 Automatic Behaviors
 Obedience [tendency to follow commands even if harmful to self]
 Echolalia
 Echopraxia

physiology behind the catatonic state. Indeed, there is no consensus in the literature regarding the phenomenology of catatonia (Table 2). As a consequence of unclear guidelines, there becomes a relative disproportionate reliance on the art and experience of medical decision-making by an individual physician. Inexperienced physicians become reluctant and hesitate to make the diagnosis and treat the condition. Catatonia is often-times relegated to “diagnosis by exclusion” or simply completely avoided.

Delaying the treatment of catatonia negatively impacts patient care, as it significantly reduces the likelihood of traditional (ECT, benzodiazepine) treatment response.¹ Thus, deferring treatment until tests return to rule out known dementias might be detrimental. In fact, catatonia and dementia are not mutually exclusive diagnoses.² The three cardinal catatonic features (little or no spontaneous movement, mutism, refusal to eat or drink) are hallmark features of advanced dementia.³ Perhaps treating the catatonic component of a patient’s dementing condition may ameliorate a reversible or modifying factor.⁴ At

least 50 neurologic conditions have been identified as direct causes of secondary catatonia symptomatology.⁵ Missing a catatonia treatment opportunity might greatly alter a patient’s level of functioning.

Not surprisingly the theories about catatonia pathophysiology and known dementias overlap considerably. Theories include deficits in cortical development, dopaminergic hypoactivity, low GABA-A receptor binding, frontal anomalies, dysfunction of norepinephrine and serotonin transmission and of course glutamatergic dysfunction.^{5,6} A recent article reviewed adjunctive glutamate antagonist therapies in the treatment of catatonia and noted possible response with medications such as amantadine, memantine and topiramate.⁶ On the other hand, modalities that are now viewed with suspicion in the demented patient, such as benzodiazepines or even ECT, might be more welcomed with further study. The literature regarding the possibility of lorazepam-responsive dementias illustrates this trend.⁷ As awareness of the catatonic state and its many varieties of presentation increases, so too might the

available multidimensional forms of treatment for both catatonia and dementia.

References

1. Caroff SN, Ungvari GS, Bhati MT, Datto CJ, O'Reardon JP. Catatonia and prediction of response to electroconvulsive therapy. *Psychiatr Ann* 2007;37:57-63.
2. Alisky JM. Is the immobility of advanced dementia a form of lorazepam-responsive catatonia? *Am J of Alzheimers Dis Other Demen* 2004;19:213-214.
3. Carroll BT, Kennedy JC, Goforth HW. Catatonic signs in medical and psychiatric catatonias. *CNS Spectr* 2000;5:66-69.
4. Salam S, Kilzieh N. Lorazepam treatment of psychogenic catatonia: an update. *J Clin Psychiatry* 1988;49 Suppl:16-21.
5. Northoff G. Brain imaging in catatonia: current findings and a pathophysiologic model. *CNS Spectr* 2000;5:34-36.
6. Carroll BT, Goforth HW, Thomas C, et al. Review of adjunctive glutamate antagonist therapy in the treatment of catatonic syndromes. *J Neuropsychiatry Clin Neurosci* 2007;19:406-412.
7. Alisky JM. Lorazepam-reversible catatonia in the elderly can mimic dementia, coma, and stroke. *Age Ageing* 2007;36:229.

Disclosure: the authors report no conflicts of interest.

All content in *Neurological Bulletin*, unless otherwise noted, is licensed under a Creative Commons Attribution-Noncommercial-Share Alike License <http://creativecommons.org/licenses/by-nc-sa/3.0/> (ISSN 1942-4043)