

2021-02-18

## Lower extremity nodules in an immunocompetent woman

Ista A. Egbeto

*University of Massachusetts Medical School*

*Et al.*

Let us know how access to this document benefits you.

Follow this and additional works at: <https://escholarship.umassmed.edu/oapubs>



Part of the [Dermatology Commons](#), and the [Skin and Connective Tissue Diseases Commons](#)

---

### Repository Citation

Egbeto IA, Trivedi A, Evan-Browning E, Levin NA. (2021). Lower extremity nodules in an immunocompetent woman. Open Access Publications by UMMS Authors. <https://doi.org/10.1016/j.jdc.2020.09.032>. Retrieved from <https://escholarship.umassmed.edu/oapubs/4608>

Creative Commons License

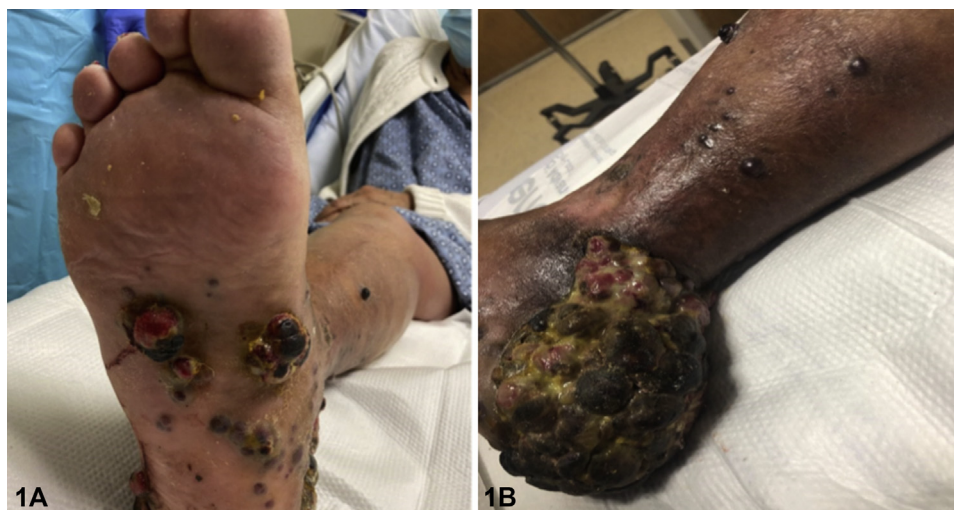

This work is licensed under a [Creative Commons Attribution-NonCommercial-No Derivative Works 4.0 License](#). This material is brought to you by eScholarship@UMMS. It has been accepted for inclusion in Open Access Publications by UMMS Authors by an authorized administrator of eScholarship@UMMS. For more information, please contact [Lisa.Palmer@umassmed.edu](mailto:Lisa.Palmer@umassmed.edu).

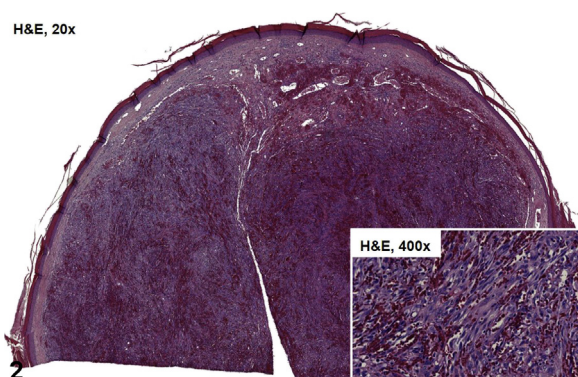
## Lower extremity nodules in an immunocompetent woman



Ista A. Egbeto, BS,<sup>a,b</sup> Apoorva Trivedi, MD,<sup>b</sup> Eric Evan-Browning, MD,<sup>b</sup> and Nikki A. Levin, MD, PhD<sup>b</sup>  
*West Boylston, Massachusetts*



**Fig 1.** Ista Ariane Egbeto, Apoorva Trivedi, MD, Eric Evan-Browning, MD, and Nikki A. Levin, MD, PhD



**Fig 2.** Ista Ariane Egbeto, Apoorva Trivedi, MD, Eric Evan-Browning, MD, and Nikki A. Levin, MD, PhD

### CASE CHALLENGE PART 1

A 79-year-old otherwise healthy Puerto Rican woman is seen for a 3-month history of a rapidly enlarging mass on her right foot. The involved areas are occasionally tender, affecting her ability to walk. Physical examination reveals many confluent, deep red to purple, eroded, grapelike nodules affecting all aspects of the foot

From Tufts University School of Medicine<sup>a</sup>; and Department of Dermatology, UMass Memorial Health Care.<sup>b</sup>

Funding sources: The authors have no funding sources to declare. IRB approval status: Not applicable.

Corresponding author: Ista A. Egbeto, Department of Dermatology, UMass Memorial Health Care, 281 Lincoln Street, Worcester, MA 01605. E-mail: [ista.egbeto@tufts.edu](mailto:ista.egbeto@tufts.edu).

JAAD Case Reports 2021;8:96-7.  
2352-5126

© 2021 by the American Academy of Dermatology, Inc. Published by Elsevier, Inc. This is an open access article under the CC BY-NC-ND license (<http://creativecommons.org/licenses/by-nc-nd/4.0/>).

<https://doi.org/10.1016/j.jdc.2020.09.032>

([Figure 1A](#)) and extending to the distal part of the leg ([Figure 1B](#)). The largest confluent mass is on the heel extending to the posterior side of the ankle ([Figure 1B](#)). She has no history of immunosuppression.

**Based on the clinical presentation and histologic features ([Figure 2](#)), what is the most likely diagnosis?**

- A. Angiosarcoma
- B. Classic Kaposi sarcoma
- C. Bacillary angiomatosis
- D. Dermatofibrosarcoma protuberans
- E. Mycetoma

Click [here](#) to view disclosures, take the quiz, and claim CME credit.

**Conflicts of interest**

The authors have no conflicts of interest to declare.