

8-1-2015

An effective approach to diagnosis and surgical repair of refractory medial epicondylitis

Amrit V. Vinod

University of Massachusetts Medical School Worcester

Glen Ross

New England Baptist Hospital

Follow this and additional works at: <http://escholarship.umassmed.edu/oapubs>

 Part of the [Musculoskeletal Diseases Commons](#), [Orthopedics Commons](#), [Sports Medicine Commons](#), and the [Surgery Commons](#)



This work is licensed under a [Creative Commons Attribution-Noncommercial-No Derivative Works 4.0 License](#).

Repository Citation

Vinod, Amrit V. and Ross, Glen, "An effective approach to diagnosis and surgical repair of refractory medial epicondylitis" (2015).

Open Access Articles. 2626.

<http://escholarship.umassmed.edu/oapubs/2626>



An effective approach to diagnosis and surgical repair of refractory medial epicondylitis



Amrit V. Vinod, BA^a, Glen Ross, MD^{b,*}

^aUniversity of Massachusetts Medical School, Worcester, MA, USA

^bNew England Baptist Hospital, Pro Sports Orthopedics, Boston, MA, USA

Background: Medial epicondylitis of the elbow, an overuse injury characterized by angiofibroblastic tenosinosis of the common flexor-pronator origin, generally responds to nonoperative treatment. Refractory cases may require surgical débridement and repair. This study discusses physical examination and imaging findings and an updated surgical technique used in patients with recalcitrant medial epicondylitis.

Methods: The surgical records of 60 patients with refractory medial epicondylitis were reviewed. All received a course of nonoperative care. After 3 to 6 months of failed therapy, imaging was obtained, and surgical intervention was offered when indicated. This open procedure consisted of thorough débridement with repair and restoration of the flexor-pronator origin, using a suture anchor. Accelerated rehabilitation, emphasizing early motion, was used. One-year follow-ups were obtained. The Mayo Elbow Performance Score was calculated preoperatively and postoperatively.

Results: Pronation weakness at 90° was a critical physical examination finding. Preoperative magnetic resonance images demonstrated pathologic partial tearing at the flexor-pronator origin. Ulnar neuritis was addressed in 20%. Postoperatively, the Mayo Elbow Performance Score significantly increased (preoperatively, 58 ± 7.7; postoperatively, 88 ± 7.8; $P = 5.6E-34$), and pain significantly decreased (preoperatively, 2.2 ± 0.3; postoperatively, 0.6 ± 0.5; $P = 3.8E-33$). There was one retear in a patient noncompliant with the postoperative protocol. He responded positively to reoperation.

Conclusion: Identification of weakness on pronation is a reliable physical examination finding for determining clinically significant pathologic changes in patients with medial epicondylitis. Débridement with restoration of the flexor-pronator origin is an efficacious procedure. In this large series of patients, surgical repair with aggressive rehabilitation was shown to be reliable and safe in restoring function and relieving pain in recalcitrant cases of medial epicondylitis.

Level of evidence: Level IV, Case Series, Treatment Study.

© 2015 The Authors. Published by Elsevier Inc. on behalf of Journal of Shoulder and Elbow Surgery Board of Trustees. This is an open access article under the CC BY-NC-ND license (<http://creativecommons.org/licenses/by-nc-nd/4.0/>).

Keywords: Medial epicondylitis; golfer's elbow; flexor-pronator tear; surgical repair; tendinosis; sports injury

The Institutional Review Board of New England Baptist Hospital provided approval for this study: No. 333362-2.

*Reprint requests: Glen Ross, MD, Pro Sports Orthopedics, 20 Guest St, Suite 225, Brighton, MA 02135, USA.

E-mail address: ross2ortho@aol.com (G. Ross).

1058-2746/© 2015 The Authors. Published by Elsevier Inc. on behalf of Journal of Shoulder and Elbow Surgery Board of Trustees. This is an open access article under the CC BY-NC-ND license (<http://creativecommons.org/licenses/by-nc-nd/4.0/>).

<http://dx.doi.org/10.1016/j.jse.2015.03.017>

Medial epicondylitis of the elbow is less commonly encountered than lateral disease, with a relative incidence of 9.8% to 20%.^{2,4,6,7,17} However, with the continuation of sports and active use of the elbow in the aging population, it is being diagnosed with increasing frequency.^{3,4,7} The

underlying etiology of medial epicondylitis is described as an angiofibroblastic tendinosis of the common flexor-pronator origin.¹⁴ It has also been characterized as a microtearing in the origin of the flexor mass.¹⁹ Specifically, the confluence of the flexor carpi radialis and pronator teres is frequently the common site of injury.^{2,9} Pain, therefore, is usually exhibited with flexion of the wrist and fingers and pronation of the forearm.³ The injury may progress to subsequent attritional partial tearing in the later stages and, in extreme cases, complete disruption of the superior flexor-pronator origin.⁹ This has been demonstrated on magnetic resonance imaging (MRI).^{8,20}

Medial epicondylitis is primarily a condition of the middle aged.^{2,7,19} Most injuries are degenerative in nature; in select cases, an acute trauma may precipitate symptoms.³ Certain sports and activities have been associated with the development of medial epicondylitis.¹⁹ The golf swing is noted to exert significant tension across the medial aspect of the elbow.⁴ Other activities involving repetitive use have also been implicated. These may include tennis, swimming, weightlifting, and work-related activities.^{2,3}

Treatment of medial epicondylitis is initially with nonoperative modalities. These include activity modification, supervised physical therapy, acupuncture, and oral analgesics and anti-inflammatories. Corticosteroid injections are often used with limited success.^{11,18} A more recent intervention, platelet-rich plasma, has been shown to be a treatment modality without significant adverse effects. It has been shown to have various clinical applications. Of note, in chronic epicondylar pain, platelet-rich plasma injections showed remarkable improvement in pain after therapy. Whereas this modality shows promise, more extensive studies will be necessary to properly validate its use.^{12,16} Conservative treatment has been shown to relieve pain in 88% to 96% of cases⁵; however, this may be dependent on the stage of presentation. Surgical intervention is indicated for refractory symptoms, typically after at least 6 months of nonoperative care. Several surgical interventions have been proposed to address the pathologic process. These may encompass open procedures, percutaneous release, and arthroscopic repair of the common flexor tendon.^{1,21}

Concomitant ulnar nerve issues may be present; 20% to 24% of refractory cases of medial epicondylitis have been cited as requiring a concomitant ulnar nerve release.¹⁹

For the past decade, we have been addressing refractory medial epicondylitis as a surgical lesion involving a discrete degenerative tear, typically located at the flexor carpi radialis/pronator teres origin. We have identified critical physical examination components that are correlated with significant pathologic changes. In addition, MRI has been used to reliably demonstrate and confirm these findings. The purpose of this study was to identify critical physical examination findings and imaging data as well as to describe surgical technique for evaluation and treatment of refractory medial epicondylitis.

Materials and methods

Study participants

A review was carried out on the records of 60 patients who underwent surgery for the treatment of refractory medial epicondylitis between 2008 and 2013. The average age was 52.5 years; 73% of the patients were male. Average duration of symptoms was 144.2 weeks from onset until surgery. The most common mechanism of injury involved participation in golf, which represented 33% of cases. This was followed by tennis, weightlifting, and construction-type activities. In 20% of patients, a concomitant ulnar nerve release was required. The decision to perform ulnar nerve release was based solely on the clinical presentation of cubital tunnel pain and ulnar neuritis; electromyography and nerve conduction studies were not indicated. This was typically performed either in situ or as a subcutaneous transposition, depending on nerve stability. Refer to [Table I](#) for a summary of the characteristics of the patients. All patients had undergone a supervised nonoperative course of treatment. The majority of patients received 1 to 3 corticosteroid injections during this time. One patient had received 8 steroid injections. Inclusion criteria consisted of the diagnosis of medial epicondylitis, without underlying instability, arthritis, or prior surgical procedures. Coexisting ulnar neuritis was not exclusionary. One patient was excluded because of multiple surgeries to the same elbow.

The diagnosis was made on a clinical basis. On physical examination, the patient typically demonstrated full range of motion without significant restriction. Tenderness to palpation can generally be isolated to a location just distal to the apex of the superior medial epicondyle, corresponding to the flexor carpi radialis/pronator origin. Pronation strength is measured on a side-to-side basis with the elbows flexed at 90°. Approximately 20 pounds of resistance is used. During preoperative assessment, partial tears of the flexor-pronator origin often result in significant weakness on testing for pronator strength. Wrist and finger flexion testing was less reliable.

After 3 to 6 months of symptoms unresponsive to nonoperative care, MRI was obtained. Standard sequences of axial, coronal, and sagittal images were employed. Typical findings included a substantial defect on water gradient coronal images consistent with partial tearing of the flexor-pronator origin ([Fig. 1](#)). No medial collateral ligament injuries were encountered. Concomitant findings were minimal.

Surgical technique

Symptomatic patients were offered surgical treatment. The average duration of time from onset of symptoms to surgery was >2 years. This may reflect a tertiary referral practice. All procedures were performed by the senior author (G.R.). The surgical procedure consisted of an open resection, with repair of the pathologic flexor-pronator origin. The incision was carried out posterior to the medial epicondyle and was typically 5 to 6 cm in length. Care was taken to avoid injury to the medial antebrachial cutaneous nerve. Soft tissues were swept superiorly, and the flexor-pronator origin was exposed ([Fig. 2, A](#)). The partially torn tissue was typically located at the confluence of the flexor carpi radialis/pronator teres interval. There is often a vertical septum in this area, which was resected.⁶ Approximately 30% of cases

Table I Characteristics of the patients

| Characteristic | Value (N = 60) |
|--|-------------------|
| Mean age \pm SD (years) | 52.5 \pm 8.8 |
| Male (%) | 44 (73.3) |
| Mean BMI \pm SD (kg/m ²) | 25.2 \pm 3.4 |
| Tobacco use (%) | 5 (8.3) |
| Symptom duration \pm SD (weeks) | 144.2 \pm 222.3 |
| Mechanism of injury (%) | |
| Golf | 20 (33.3) |
| Tennis | 10 (16.7) |
| Weightlifting | 9 (15) |
| Construction/work related | 8 (13.3) |
| Attrition | 5 (8.3) |
| Rock climbing | 1 (1.7) |
| Bowling | 1 (1.7) |
| Other | 6 (10) |
| Concomitant ulnar nerve release (%) | 12 (20) |
| Chronic symptoms (%) | 46 (76.7) |

BMI, body mass index; SD, standard deviation.

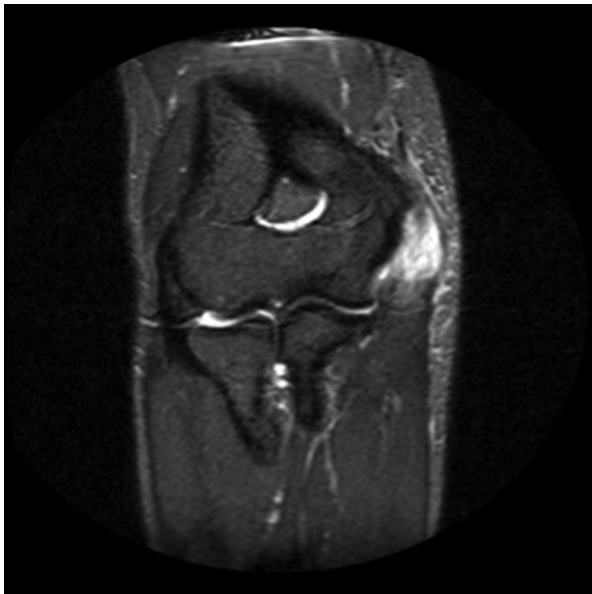


Figure 1 Representative coronal T2 magnetic resonance image of a patient with medial epicondylitis. Greatest signal intensity near the flexor-pronator origin indicates tearing of the tendon.

demonstrated pathologic change that was immediately apparent in the superficial tissues; 70% of cases required a shallow, 2-mm, longitudinal incision to be made directly over the area of suspected injury.

Once the partially torn, degenerative tissue was exposed, it was liberally resected. This was typically in an oval or elliptical fashion. Once this was completed, the medial epicondyle itself was lightly débrided with a curet and rongeur. Repair typically consisted of side-to-side suturing with an absorbable suture (Fig. 2, B). Final repair back to bone consisted of placement of a 3.0-mm biocomposite suture anchor (Arthrex, Naples, FL, USA), with the permanent sutures exchanged for 2 absorbable No. 1 polydioxanone sutures. Free needles were used to place 2 sets of

horizontal mattress sutures from the suture anchor to the medial epicondyles to effect repair and to allow restoration of the pronator origin back to the medial epicondyle.

Once the repair was completed, the elbow was placed through a full range of motion to ensure that the repair was stable. Subcutaneous tissues and skin were closed in standard fashion.

Postoperative rehabilitation

Postoperatively, patients were placed in a simple sling. After 48 hours, active range of motion exercises were initiated. Sutures were removed at 2 weeks postoperatively, and patients were allowed to perform all light activities of daily living. Strengthening began at 6 to 8 weeks postoperatively. Return to sports and repetitive activities, such as golf, was allowed after 3 to 4 months and on an individual basis. All patients were clinically observed for 1 year. Complications were tabulated.

Measure of outcomes

Elbow function was assessed with the Mayo Elbow Performance Score (MEPS) metric.¹³ The score was calculated for each patient's first visit and compared with the score at 1 year postoperatively. Obtaining each score involved quantifying patients' self-reported pain as well as assessing elbow function, stability, and strength. Strength was quantified as the degree of weakness on resisted pronation, as this is the motion that causes the greatest difficulty in patients with medial epicondylitis. Data were analyzed by a paired sample *t* test ($\alpha = .02$). To determine pain score, patients' self-reported pain level was quantified as follows: 0, no pain; 1, mild pain; 2, moderate pain; and 3, severe pain. Data were analyzed in a similar manner.

Results

Postoperative outcomes

MEPS was used for objective assessment of the patients' outcomes. Final tabulation of scores was obtained at 1 year postoperatively. Preoperative scores averaged 58, whereas postoperative MEPS averaged 88 (Table II). This was noted to be highly significant ($P < .02$). Pain findings are summarized in Table III. Average preoperative pain score was 2.2, corresponding to moderate to severe pain, whereas postoperative pain score was 0.6, indicating nonexistent or mild pain.

Complications

There were no significant complications in this series. Specifically, no infections, ulnar nerve injuries, or elbow stiffness were encountered. One patient required reoperation for pain and re-tearing at 1.5 years after his index procedure. He had returned to national-level competitive swimming against medical advice within 3 months of his initial surgery. At re-exploration, he had significant scarring and re-tearing of his flexor-pronator origin. After this was

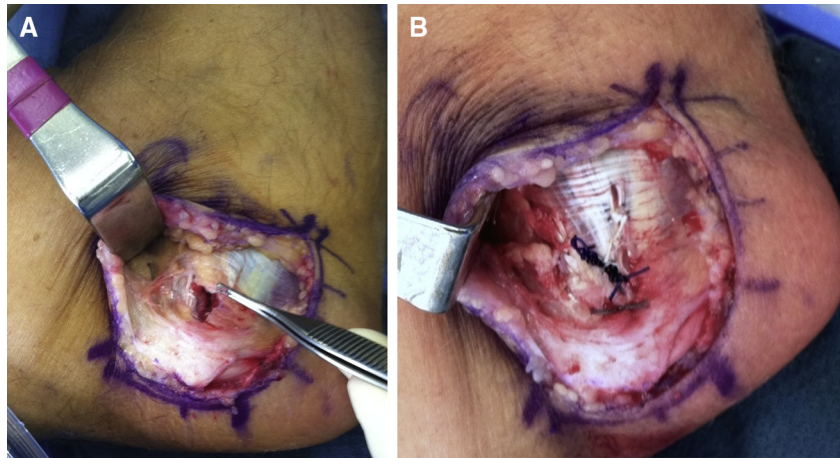


Figure 2 Before and after surgical repair of the torn flexor carpi radialis/pronator teres tendon. (A) Tear of the flexor carpi radialis/pronator teres conjoined tendon. (B) Repaired tendon.

Table II MEPS comparison before and after surgical treatment

| | |
|--|--------------|
| Preoperative \pm SD | 58 \pm 7.7 |
| Postoperative \pm SD | 88 \pm 7.8 |
| <i>P</i> value (1-tailed, paired sample <i>t</i> test) | <.0001 |

MEPS, Mayo Elbow Performance Score; SD, standard deviation. Elbow function significantly improved postoperatively.

addressed, he eventually had an excellent outcome and returned to competition pain free. Another patient had a mild degree of residual pain that did not warrant further intervention. He was satisfied with his outcome.

Pathology

All resected tissue underwent pathologic evaluation. These specimens demonstrated fibrodegenerative tendinous tissue without a significant inflammatory component. Granulation tissue and a healing reparative response were occasionally seen.

Specific case example

A 60-year-old, male, competitive right-hand golfer had 4 to 5 months of medial elbow pain, without significant trauma. Physical therapy and a single corticosteroid injection allowed him to return to competitive play with some degree of pain. Three weeks before presentation, he struck a rock with his golf club, resulting in exacerbation of medial elbow pain. On physical examination, he had severe tenderness just distal to the medial epicondyle, full range of motion, and profound weakness of pronation strength. MRI demonstrated significant high-grade tearing of the flexor pronator origin (Fig. 1). He had inability to return to competitive golf and elected to proceed with surgical treatment.

Table III Pain comparison before and after surgical treatment

| | |
|--|---------------|
| Preoperative \pm SD | 2.2 \pm 0.3 |
| Postoperative \pm SD | 0.6 \pm 0.5 |
| <i>P</i> value (1-tailed, paired sample <i>t</i> test) | <.0001 |

Pain scale key

- 0: No pain
- 1: Mild pain
- 2: Moderate pain
- 3: Severe pain

SD, standard deviation.

Surgery markedly reduced the patients' pain.

Operative findings demonstrated a high-grade partial disruption of the superior flexor-pronator origin (Fig. 2, A). This was meticulously débrided, and the epicondyle was prepared for restoration of the flexor-pronator unit. By a combination of a suture anchor and side-to-side sutures, the flexor-pronator origin was restored (Fig. 2, B). He returned to playing golf at 4 months and at 1 year was pain free and competitively playing.

Discussion

Medial epicondylitis can be manifested as a spectrum of pathologic changes ranging from tendinosis to significant partial tears of the flexor-pronator origin. Our clinical experience of 60 patients treated surgically for refractory partial tears represents, to our knowledge, the largest series reported to date.

Sports-related activities seemed to be the most common cause of medial epicondylitis in the patients analyzed in this study (76.7%). All patients were able to return to their usual level of activity, including the patient who required revision because of reinjury. In addition, Kurvers and

Verhaar⁹ showed that surgical repair on patients diagnosed with medial epicondylitis with concomitant ulnar neuritis had poorer outcomes postoperatively; however, this was not our experience.

Several aspects of the diagnosis and treatment warrant emphasis. Patients presenting with refractory, severe symptoms can often be diagnosed clinically, with a targeted examination. We have found with great reproducibility that careful evaluation of pronation strength at 90° of flexion routinely uncovers both measurable weakness and pain. Side-to-side comparative testing confirmed this in patients with significant pathologic change of the flexor pronator origin. Although this has been mentioned in prior studies, we believe that it should be emphasized as a key physical examination component for the evaluation.

Both ultrasound and MRI have been shown to be very helpful in the evaluation of refractory medial epicondylitis. Ultrasound has been proven to be both a sensitive and specific diagnostic.¹⁵ In general, MRI is preferred in patients who may also have concomitant ulnar neuritis and medial instability.²⁰ MRI was chosen for this study mainly because of the former. The use of MRI for confirmation of the pathologic process has been helpful and reproducible in demonstrating definable pathologic change at the medial epicondyle. Whereas its routine use early in the clinical course is not advocated, it can be of assistance to the clinician when significant injury is suspected that is unresponsive to nonoperative care.²⁰ MRI not only allows thorough imaging of the flexor-pronator origin but can also be used to diagnose ulnar collateral ligament tears and subtle arthrosis of the medial compartment of the elbow. We believe this allows a more precise evaluation in surgical candidates, as this confirms significant pathologic changes in most cases, which should improve overall outcomes with operative intervention.

Surgical intervention has consistently been shown to significantly improve the symptoms of recalcitrant medial epicondylitis. Initially, tendon release procedures were relied on to treat patients with medial epicondylitis.¹ Although this procedure mitigated pain, it left patients vulnerable to valgus instability.¹⁴ Since then, various reattachment protocols have been published, each with varying degrees of success. Vangsness and Jobe¹⁹ reported the postoperative outcome of 35 patients to be excellent in 24 patients, good in 10 patients, and fair in 1 patient. Ollivierre et al¹⁴ published a similar technique and reported that all patients were pain free postoperatively. Of note, 10 of the 48 patients in their study were not able to return to their sporting or occupational activities. Five of these cases were related to pain on performing their respective activities.¹⁴ Recently, Kwon et al¹⁰ reported a fascial elevation and tendon origin resection protocol, in which 20 patients experienced approximately 90% reduction in pain, and 18 of the 20 patients were satisfied with their outcomes.

Our surgical technique differs slightly from prior procedures. Early on, the senior author performed a débridement of the pathologic tissue, followed by a suture repair of the remaining flexor-pronator origin. However, some patients still had slight clinically measurable pronator weakness on manual muscle strength testing. Therefore, for the past 11 years, a small suture anchor has been added to all patients receiving surgical treatment for this condition. After débridement of the pathologic tissue, the flexor-pronator tendon unit is securely restored with a small double-loaded suture anchor placed in the medial epicondyle. The permanent suture is exchanged for an absorbable No. 1 polydioxanone suture to prevent irritation. A double horizontal mattress configuration is employed. We believe this offers several advantages. The flexor-pronator origin is securely restored by this technique with minimal risk of compromising the tendon. This allows tendon restoration and has been observed to offer a clinical improvement in strength. Whereas transosseous sutures may be used, they may cause ulnar nerve irritation and are less secure. We have experienced only 1 failure with this technique, in a noncompliant competitive swimmer.

Postoperative rehabilitation was expedited because of the secure nature of the repair, after débridement. Intraoperatively, the elbow is placed through a full range of motion under direct visualization to ensure integrity of the repair. The patient is encouraged to begin active motion of the elbow on the first or second postoperative day as comfort allows. Patients are allowed use of the elbow for light activity and daily living for 6 weeks, at which time a brief strengthening program is started. Return to sports is delayed, however, until approximately 4 months from surgery. Outcomes from this intervention have been highly satisfactory.

This study has several limitations. First, it is a retrospective study, and certain inherent biases may be present. We attempted to address this limitation by standardizing the preoperative protocol for all patients. This included a minimal 4-month period of nonoperative care, including physical therapy, oral nonsteroidal anti-inflammatory drugs, cortisone injections, and avoidance of inciting activities. Similarly, postoperative clinic visits and rehabilitation were similar for all patients. Whereas our approach in addressing these biases seemed adequate, a prospective study would unequivocally determine the feasibility and efficacy of using a suture anchor. Second, only 1-year follow-ups were performed postoperatively. MEPS comparison demonstrated substantial improvement 1 year after surgery. It has been our experience that these results are stable, and deterioration does not typically occur after 1 year. Although a longer follow-up period would be preferred, we have not seen failure or regression of results with this technique after 1 year. Last, this study sought to measure the effectiveness of essentially 4 distinct variables, namely, using a single physical examination finding for diagnosis, obtaining MRI studies to confirm diagnosis, employing a unique surgical

technique, and finally using an aggressive rehabilitation program. It is uncertain how effective each variable is in isolation because such an assessment would require control groups. It can be stated with fair certainty, however, that in combination, these 4 variables offer a safe and efficacious method of handling severe medial epicondylitis.

Whereas there are some limitations, the strengths of this study are many, the first of which is the large sample size. Second, all patients received imaging, and all were validated with outcome measurements postoperatively. There was no loss to follow-up. All the patients were satisfied with the outcome of their surgery. In addition, every patient was eventually able to return to full participation in prior activities. These results suggest that the 4 approaches employed here are adequate in managing refractory medial epicondylitis.

Conclusion

Severe medial epicondylitis can be successfully addressed with a thorough understanding of the anatomic pathology and surgical intervention. We believe that advanced diagnostic imaging and an expedited rehabilitation program can improve outcomes for patients as well as the patient's acceptance and satisfaction. Return to sports and activities can be reliably obtained in most cases.

Disclaimer

The authors, their immediate families, and any research foundation with which they are affiliated have not received any financial payments or other benefits from any commercial entity related to the subject of this article.

Acknowledgment

Scott P. Steinmann, MD, for his editorial support.

Supplementary data

Supplementary data related to this article can be found at <http://dx.doi.org/10.1016/j.jse.2015.03.017>.

References

1. Baumgard SH, Schwartz DR. Percutaneous release of the epicondylar muscles for humeral epicondylitis. *Am J Sports Med* 1982;10:233-6.
2. Ciccotti MC, Schwartz MA, Ciccotti MG. Diagnosis and treatment of medial epicondylitis of the elbow. *Clin Sports Med* 2004;23:693-705. <http://dx.doi.org/10.1016/j.csm.2004.04.011>
3. Ciccotti MG, Charlton WPH. Epicondylitis in the athlete. *Clin Sports Med* 2001;20:77-93.
4. Ciccotti MG, Ramani MN. Medial epicondylitis. *Tech Hand Up Extrem Surg* 2003;7:190-6.
5. Gabel GT, Morrey BF. Operative treatment of medial epicondylitis. Influence of concomitant ulnar neuropathy at the elbow. *J Bone Joint Surg Am* 1995;77:1065-9.
6. Gabel GT, Morrey BF. Medial epicondylitis. In: Morrey BF, Sanchez-Sotelo J, editors. *The elbow and its disorders*. Philadelphia: Saunders; 2008. p. 638-44 (ISBN No. 978-1416029021).
7. Hamilton PG. The prevalence of humeral epicondylitis: a survey in general practice. *J R Coll Gen Pract* 1986;36:464-5.
8. Kijowski R, De Smet AA. Magnetic resonance imaging findings in patients with medial epicondylitis. *Skeletal Radiol* 2005;34:196-202. <http://dx.doi.org/10.1007/s00256-005-0896-9>
9. Kurvers H, Verhaar J. The results of operative treatment of medial epicondylitis. *J Bone Joint Surg Am* 1995;77:1374-9.
10. Kwon BC, Kwon YS, Bae KJ. The fascial elevation and tendon origin resection technique for the treatment of chronic recalcitrant medial epicondylitis. *Am J Sports Med* 2014;42:1731-7. <http://dx.doi.org/10.1177/0363546514530664>
11. Marmor L. Medial epicondylitis. *Calif Med* 1959;91:23.
12. Mishra A, Pavelko T. Treatment for chronic elbow tendinosis with buffered platelet-rich plasma. *Am J Sports Med* 2006;34:1774-8. <http://dx.doi.org/10.1177/0363546506288850>
13. Morrey BF, An KN. Functional evaluation of the elbow. In: Morrey BF, Sanchez-Sotelo J, editors. *The elbow and its disorders*. Philadelphia: Saunders; 2008. p. 80-91 (ISBN No. 978-1416029021).
14. Ollivierre CO, Nirschl RP, Pettrone FA. Resection and repair for medial tennis elbow a prospective analysis. *Am J Sports Med* 1995;23:214-21.
15. Park GY, Lee SM, Lee MY. Diagnostic value of ultrasonography for clinical medial epicondylitis. *Arch Phys Med Rehabil* 2008;89:738-42. <http://dx.doi.org/10.1016/j.apmr.2007.09.048>
16. Sampson S, Gerhardt M, Mandelbaum B. Platelet rich plasma injection grafts for musculoskeletal injuries: a review. *Curr Rev Musculoskelet Med* 2008;1:165-74. <http://dx.doi.org/10.1007/s12178-008-9032-5>
17. Schwartz MA, Ciccotti MC, Ciccotti MG. Open treatment of medial epicondylitis. *Tech Orthop* 2006;21:283-9. <http://dx.doi.org/10.1097/01.bto.0000252146.11900.b2>
18. Stahl S, Kaufman T. The efficacy of an injection of steroids for medial epicondylitis. A prospective study of sixty elbows. *J Bone Joint Surg Am* 1997;79:1648-52.
19. Vangsness CT Jr, Jobe FW. Surgical treatment of medial epicondylitis. Results in 35 elbows. *J Bone Joint Surg Br* 1991;73:409-11.
20. Walz DM, Newman JS, Konin GP, Ross G. Epicondylitis: pathogenesis, imaging, and treatment. *Radiographics* 2009;30:167-85. <http://dx.doi.org/10.1148/rg.301095078>
21. Zonno A, Manuel J, Merrell G, Ramos P, Akelman E, DaSilva MF. Arthroscopic technique for medial epicondylitis: technique and safety analysis. *Arthroscopy* 2010;26:610-6. <http://dx.doi.org/10.1016/j.arthro.2009.09.017>