

University of Massachusetts Medical School

eScholarship@UMMS

---

Infectious Diseases and Immunology  
Publications

Infectious Diseases and Immunology

---

2016-02-01

## Uveitis and Systemic Inflammatory Markers in Convalescent Phase of Ebola Virus Disease

John R. Chancellor

*University of Massachusetts Medical School*

*Et al.*

Let us know how access to this document benefits you.

Follow this and additional works at: [https://escholarship.umassmed.edu/infdis\\_pp](https://escholarship.umassmed.edu/infdis_pp)



Part of the Allergy and Immunology Commons, Eye Diseases Commons, Immunology and Infectious Disease Commons, Infectious Disease Commons, Ophthalmology Commons, Pathological Conditions, Signs and Symptoms Commons, and the Virus Diseases Commons

---

### Repository Citation

Chancellor JR, Padmanabhan SP, Greenough TC, Sacra R, Ellison RT, Madoff LC, Droms R, Hinkle D, Asdourian G, Finberg RW, Stroher U, Uyeki TM, Cerón OM. (2016). Uveitis and Systemic Inflammatory Markers in Convalescent Phase of Ebola Virus Disease. Infectious Diseases and Immunology Publications. <https://doi.org/10.3201/eid2202.151416>. Retrieved from [https://escholarship.umassmed.edu/infdis\\_pp/406](https://escholarship.umassmed.edu/infdis_pp/406)

This material is brought to you by eScholarship@UMMS. It has been accepted for inclusion in Infectious Diseases and Immunology Publications by an authorized administrator of eScholarship@UMMS. For more information, please contact [Lisa.Palmer@umassmed.edu](mailto:Lisa.Palmer@umassmed.edu).

# Uveitis and Systemic Inflammatory Markers in Convalescent Phase of Ebola Virus Disease

John R. Chancellor,<sup>1</sup> Sriranjani P. Padmanabhan,<sup>1</sup>  
Thomas C. Greenough, Richard Sacra,  
Richard T. Ellison III, Lawrence C. Madoff,  
Rebecca J. Droms, David M. Hinkle,  
George K. Asdourian, Robert W. Finberg,  
Ute Stroher, Timothy M. Uyeki, Olga M. Cerón

We report a case of probable Zaire Ebola virus–related ophthalmologic complications in a physician from the United States who contracted Ebola virus disease in Liberia. Uveitis, immune activation, and nonspecific increase in antibody titers developed during convalescence. This case highlights immune phenomena that could complicate management of Ebola virus disease–related uveitis during convalescence.

## The Case-Patient

Fever developed in a physician providing health care in Liberia on August 29th, 2014 (day 0). The physician was positive for EBOV by reverse transcription PCR (RT-PCR) of plasma and was evacuated to the United States. Details of his acute phase clinical course and management were recently described (1).

The patient was given investigational drug TKM-100-802 siRNA LNP (Tekmira Pharmaceuticals, Burnaby, British Columbia, Canada). He also received convalescent-phase plasma from a survivor of EVD on day 9. During hospitalization, bilateral conjunctivitis (1) developed, but it resolved. He did not undergo formal ophthalmologic examination or report ocular symptoms and was discharged on day 26.

The patient came to the UMass Memorial Medical Center (Worcester, MA, USA) 37 days after onset of EVD with a 2-day history of nonproductive cough, low-grade fever, and generalized weakness. He was given azithromycin for suspected pneumonia. The patient reported irritation and redness of the left eye and was given topical polymyxin B sulfate/trimethoprim for presumed conjunctivitis. Blood cultures and nasal wash and swab specimens were negative for respiratory

pathogens (online Technical Appendix, <http://wwnc.cdc.gov/EID/article/22/2/15-1416-Techapp1.pdf>). RT-PCR result for a plasma specimen was negative for EBOV RNA.

The patient came to the UMass Memorial Eye Center on October 7, 2014 (day 40), with a 1-day history of painful vision loss, redness, and photophobia of the left eye. Results of review of other systems were negative. His medical history included treated latent tuberculosis and presumed acute Lyme disease treated in June 2014 with doxycycline.

He reported no history of ocular problems. Best corrected visual acuity was 20/25 in the right eye and 20/70 in the left eye. Intraocular pressures were 20 mm Hg in the right eye and 8 mm Hg in the left eye. Results of examination of the right eye were not remarkable. Slit lamp examination of the left eye showed diffuse blood vessel injection, mild corneal edema with fine inferior keratic precipitates, fibrin reaction, and leukocytes in the anterior chamber without hypopyon (Figure 1). The anterior vitreous humor was clear. The left fundus viewed by indirect ophthalmoscopy was hazy because of anterior segment findings but showed a grossly normal posterior segment. The patient was initially given topical 1% topical prednisolone acetate (every hour while awake) and 1% homatropine (2×/d). These drugs were gradually tapered over several weeks as he showed clinical improvement.

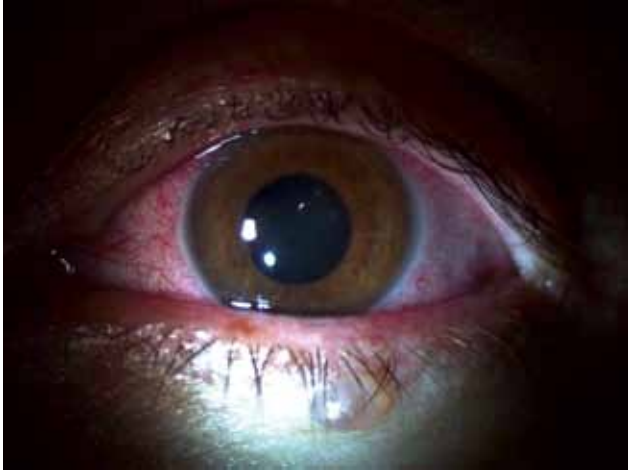EBOV transmission was a concern because of reports of prolonged viral shedding on the ocular surface (2–4). After consent was obtained, the patient remained in home isolation pending results of conjunctival swab specimen testing. On day 42, one dry conjunctival swab specimen and 1 conjunctival swab specimen (in viral transport medium) from the inferior fornix of each eye were collected (online Technical Appendix). Specimens were shipped to the Centers for Disease and Prevention (CDC; Atlanta, GA, USA), and all showed negative results by RT-PCR for EBOV RNA.

On day 50, the patient had worsened best corrected visual acuity in the left eye (20/200) and increased floaters despite improved anterior chamber findings. Fundus examination demonstrated vitreous haze (standardization of uveitis nomenclature [5] classification grade 2–3 and classification grade 6 of Davis et al. [6]). No choroidal or retinal lesions were noted. Spectral domain ocular coherence tomography (Heidelberg Engineering, Carlsbad, CA, USA) showed diffuse vitreous opacity and vitreous adhesions that appeared as small particles in a line of vitreous strands (Figure 2). In addition, In addition, spectral domain–optical coherence

Author affiliations: University of Massachusetts Medical School, Worcester, Massachusetts, USA (J.R. Chancellor, S.P. Padmanabhan, T.C. Greenough, R. Sacra, R.T. Ellison III, L.C. Madoff, R.J. Droms, D.M. Hinkle, G.K. Asdourian, R.W. Finberg, O.M. Cerón); Massachusetts Department of Public Health, Boston, Massachusetts, USA (L.C. Madoff); Centers for Disease Control and Prevention, Atlanta, Georgia, USA (U. Stroher, T.M. Uyeki)

DOI: <http://dx.doi.org/10.3201/eid2202.151416>

<sup>1</sup>These authors contributed equally to this article.



**Figure 1.** Slit lamp examination of the left eye of a physician from the United States who contracted Ebola virus disease in Liberia and had eye inflammation develop during convalescence. Image shows diffuse conjunctival injection, mild corneal edema with fine inferior keratic precipitates, fibrin reaction, and leukocytes in the anterior chamber without hypopyon. Used with permission of the patient.

tomography imaging showed cystoid macular edema and vitreous adhesions tethered to the optic disc.

Diagnostic studies for etiologies of uveitis were performed on day 54. Results were positive for human leukocyte antigen (HLA)–B27 haplotype. We found increased levels of IgM and IgG against cytomegalovirus, Epstein-Barr virus, and varicella zoster virus. Lyme disease screening with confirmatory Western blot showed IgM against *Borrelia burgdorferi* (IgG Western blot result was

negative). The perinuclear–antineutrophil cytoplasmic antibody titer was 1:80, and the erythrocyte sedimentation rate (48 mm/h) was increased. Complete laboratory data are shown in the online Technical Appendix. The patient showed persistence of EBOV RNA virus in semen during convalescence (CDC, unpub. data).

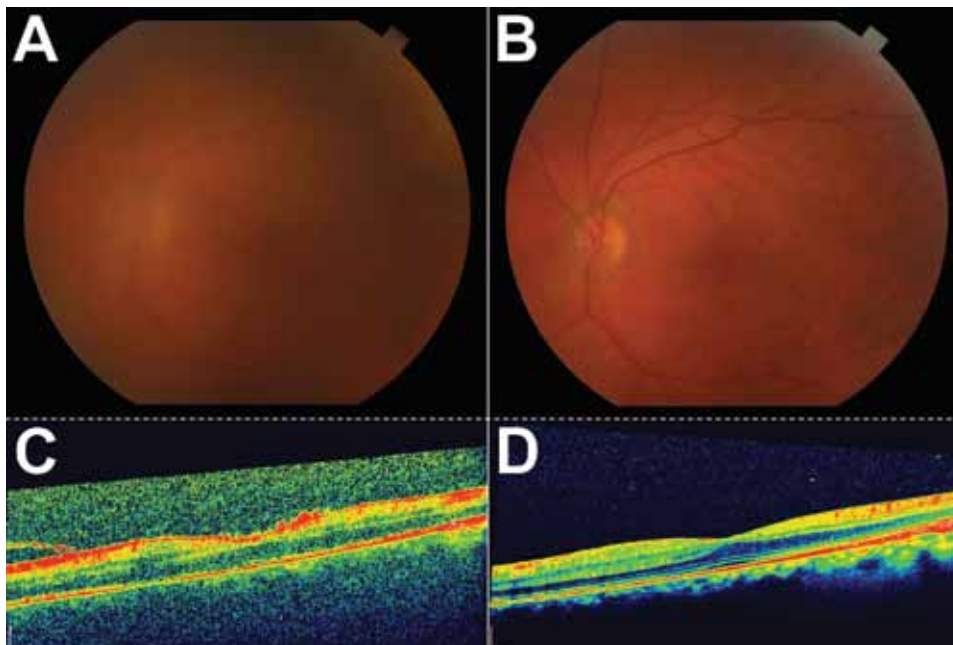
The patient was given prednisone (60 mg/d), and posterior segment inflammation had improved at follow-up 4 days later. Intraocular fluid sampling was considered for identifying EBOV RNA in aqueous or vitreous humors pending progress of the clinical course of the patient, but because his ocular inflammation responded well to medical therapy, this sampling was deferred.

Tapering of prednisone was initiated 1 week after treatment. Seven weeks (day 89) after initial presentation, left eye visual acuity increased to 20/25. As of March 2015, the patient was asymptomatic and his visual acuity was 20/20. The posterior segment was clear, and repeat spectral domain ocular coherence tomography confirmed normal macular structure (Figure 2).

We implemented universal precautions during examinations and designated 1 examination room and a set of equipment for office visits. Personal protective equipment used is detailed in the online Technical Appendix. Signs or symptoms of illness did not develop in any staff who cared for the patient.

## Conclusions

EVD evolved in December 2013 from a regional outbreak in West Africa to a major global health concern (7). As the number of survivors of Ebola increases, evaluation of



**Figure 2.** Color fundus and optical coherence tomography (OCT) images during active uveitis and after resolution for a physician from the United States who contracted Ebola virus disease in Liberia and had eye inflammation develop during convalescence. A) Color fundus image of the left eye showing a hazy view to the posterior pole during active uveitis (standardization of uveitis nomenclature classification grade 2–3). B) Color fundus image of the left eye showing a clear view to the posterior pole after resolution of uveitis. C) OCT of macula showing vitreous debris and small particles in a line of vitreous strands, consistent with inflammatory debris. D) OCT of macula showing resolution of vitreous and inflammatory debris. Scale bars indicate 200  $\mu\text{m}$ .

ocular disease, particularly uveitis, will be a major component of patient management. Evaluation of non-EVD causes of uveitis in this patient showed notable results. First, he was positive for HLA-B27. This major histocompatibility class I allele has a well-recognized association with anterior uveitis (8). It is unclear whether this HLA status contributed to development of uveitis in the context of recent EVD. Second, there was evidence of global immune activation (increased erythrocyte sedimentation rate) and dysregulation of antibody production given the broad spectrum of positive serologic results, all of which fully returned to reference values on repeat testing after corticosteroid treatment (online Technical Appendix).

Lymphocyte responses have been described in humans with EVD, and sustained responses have been noted up to 60 days after symptom onset (9). Prolonged presence of activated virus-specific lymphocytes might be caused by retained viral antigen despite undetected EBOV viral load. Antibody-producing plasmablasts levels increased during acute EVD, and measures of EBOV-specific responses suggested polyclonal expansion, including cells with other specificities (9). The pronounced increase in levels of serologic markers observed for this patient suggests that dysregulation of antibody production might contribute to immunopathogenesis and provides supporting evidence of a robust inflammatory response during EVD. Health care providers should be aware that the usual laboratory workup for uveitis might be confounding in the setting of recent EBOV infection.

We considered the possibility of an immune reaction secondary to recent treatment with TKM-100-802 siRNA LNP and convalescent-phase plasma from survivors of EVD. However, little data are available regarding these treatments and immune potentiation or uveitis. Larger trials would be necessary to evaluate these potential associations.

Similar to results of Varkey et al. (10), we did not detect EBOV RNA in conjunctival samples. However, the findings of viable EBOV persisting in aqueous humor during convalescence (10) and EBOV in semen in convalescent-phase samples (2,11) provides evidence that EBOV is harbored in immune-privileged organs. EBOV RNA was detected in semen specimens from our patient, and testing has yielded positive results (CDC, unpub. data). It remains unclear whether EVD-associated uveitis is caused by cytopathic effect of the virus or immune response, but early use of systemic corticosteroids appears to be beneficial, and sampling of intraocular fluid might not be necessary in patients who clinically improve with medical therapy.

### Acknowledgments

We thank Deborah Mack, the Diagnostic Imaging and Clinical Staff of the UMass Memorial Eye Center, the Massachusetts Department of Public Health, and Angela Hewlett for their

contributions to the study and Amy Schuh for performing RT-PCRs for conjunctival specimens.

Mr. Chancellor is a senior medical student at the University of Massachusetts Medical School, Worcester, Massachusetts. His research interests are ophthalmology and infectious diseases. Dr. Padmanabhan is an Assistant Professor of Ophthalmology at the University of Massachusetts Medical School, Worcester, Massachusetts. Her research interests are glaucoma and worldwide prevention of blindness.

### References

1. Kraft CS, Hewlett AL, Koepsell S, Winkler AM, Kratochvil CJ, Larson L, et al. The use of TKM-100802 and convalescent plasma in 2 patients with Ebola virus disease in the United States. *Clin Infect Dis*. 2015;61:496–502. <http://dx.doi.org/10.1093/cid/civ334>
2. Rodriguez LL, De Roo A, Guimard Y, Trappier SG, Sanchez A, Bressler D, et al. Persistence and genetic stability of Ebola virus during the outbreak in Kikwit, Democratic Republic of the Congo, 1995. *J Infect Dis*. 1999;179(Suppl 1):S170–6. <http://dx.doi.org/10.1086/514291>
3. Kibadi K, Mupapa K, Kuvula K, Massamba M, Ndaberey D, Muyembe-Tamfum JJ, et al. Late ophthalmologic manifestations in survivors of the 1995 Ebola virus epidemic in Kikwit, Democratic Republic of the Congo. *J Infect Dis*. 1999;179(Suppl 1):S13–4. <http://dx.doi.org/10.1086/514288>
4. Bwaka MA, Bonnet MJ, Calain P, Colebunders R, De Roo A, Guimard Y, et al. Ebola hemorrhagic fever in Kikwit, Democratic Republic of the Congo: clinical observations in 103 patients. *J Infect Dis*. 1999;179(Suppl 1):S1–7. <http://dx.doi.org/10.1086/514308>
5. Jabs DA, Nussenblatt RB, Rosenbaum JT; Standardization of Uveitis Nomenclature (SUN) Working Group. Standardization of uveitis nomenclature for reporting clinical data. Results of the First International Workshop. *Am J Ophthalmol*. 2005;140:509–16.
6. Davis JL, Madow B, Cornett J, Stratton R, Hess D, Porciatti V, et al. Scale for photographic grading of vitreous haze in uveitis. *Am J Ophthalmol*. 2010;150:637–41. <http://dx.doi.org/10.1016/j.ajo.2010.05.036>
7. WHO Ebola Response Team. Ebola virus disease in West Africa: the first 9 months of the epidemic and forward projections. *N Engl J Med*. 2014;371:1481–95. <http://dx.doi.org/10.1056/NEJMoa1411100>
8. Chang JH, McCluskey PJ, Wakefield D. Acute anterior uveitis and HLA-B27. *Surv Ophthalmol*. 2005;50:364–88. <http://dx.doi.org/10.1016/j.survophthal.2005.04.003>
9. McElroy AK, Akondy RS, Davis CW, Ellebedy AH, Mehta AK, Kraft CS, et al. Human Ebola virus infection results in substantial immune activation. *Proc Natl Acad Sci U S A*. 2015;112:4719–24. <http://dx.doi.org/10.1073/pnas.1502619112>
10. Varkey JB, Shantha JG, Crozier I, Kraft CS, Lyon GM, Mehta AK, et al. Persistence of Ebola virus in ocular fluid during convalescence. *N Engl J Med*. 2015;372:2423–7. <http://dx.doi.org/10.1056/NEJMoa1500306>
11. Christie A, Davies-Wayne GJ, Cordier-Lasalle T, Blackley DJ, Laney AS, Williams DE, et al. Possible sexual transmission of Ebola virus—Liberia, 2015. *MMWR Morb Mortal Wkly Rep*. 2015;64:479–81.

Address for correspondence: Olga M. Cerón, Department of Ophthalmology, University of Massachusetts Medical School, UMass Memorial Eye Center, 281 Lincoln St, 3rd Floor, Worcester, MA 01605, USA; email: [olga.ceron@umassmemorial.org](mailto:olga.ceron@umassmemorial.org)

# Uveitis and Systemic Inflammatory Markers in Convalescent Phase of Ebola Virus Disease

## Technical Appendix

### Conjunctival Swab Specimen Collection during Ebola Virus Disease

1) Don (put on) personal protective equipment (PPE) in compliance with Centers for Disease Control and Prevention (CDC) recommendations during hospitalization for Ebola virus disease (1). When collecting specimens from patients who have recovered from Ebola virus disease, standard, contact, and droplet precautions should be followed. 2) Clean periorbital skin with sterile saline or sterile water and apply topical anesthetic as needed. 3) Pass a dry swab over the right lower conjunctival sac 5–6 times to obtain epithelial cells. 4) Immediately place swab into tube of viral transport medium. 5) Repeat the above process for the left eye. 6) Repeat for the right eye and left eye for a total of 2 swab specimens in viral transport medium for each eye. 7) Obtain 2 sets of swab specimens for each eye in a similar fashion for transport in dry containers (dry swab samples). 8) Doff (take off) PPE in compliance with CDC recommendations (1). 9) Contact the state public health department and refer to CDC guidance on collection, labeling, laboratory handling, transport, and submission of specimens potentially contaminated with Ebola virus (2).

### Personal Protective Equipment

Standard, contact, and droplet precautions are recommended when evaluating patients who have survived Ebola virus disease and have ocular complications. Health care personnel must be trained and competent in correct use of recommended PPE, and a trained observer should monitor and confirm adherence to the proper use of PPE by others.

## References

- Centers for Disease Control and Prevention. Guidance on personal protective equipment to be used by healthcare workers during management of patients with Ebola virus disease in US hospitals, including procedures for putting on (donning) and removing (doffing) [cited 2015 Jul 1.] <http://www.cdc.gov/vhf/ebola/healthcare-us/ppe/guidance.html>
- Centers for Disease Control and Prevention. Guidance for collection, transport and submission of specimens for Ebola virus testing [cited 2015 Jul 1]. <http://www.cdc.gov/vhf/ebola/healthcare-us/laboratories/specimens.html>

**Technical Appendix Table 1.** Laboratory results for possible etiology of uveitis in patient with Ebola virus disease, October 2014\*

Test	Result	Comment	Reference value or range
ANCA screening with MPO/PR3, reflex to ANCA titer	P-ANCA positive	High	NA
Myeloperoxidase antibody titer	<1.0	Negative	<1.0: no antibody detected; ≥1.0: antibody detected
Proteinase 3 antibody titer	<1.0	Negative	<1.0: no antibody detected; ≥1.0: antibody detected
Complement C3c, mg/dL	85	Low	90–180
Complement C4c, mg/dL	15	Low	16–47
Complement C50, total, U/mL	41	Negative	31–60
CRP, mg/L	<1.0	Negative	<10
ESR, Westergren, mm/h	48	High	0–20
Rheumatoid factor, IU/mL	12	Negative	<14
Cyclic citrullinated peptide IgG titer, U	<1:16	Negative	<20: negative; 20–39: weak positive; 40–59: moderate positive; >59: strong positive
Cytomegalovirus IgG titer	3.98, positive	High	≤0.90: negative; 0.91–1.09: equivocal; ≥1.10: positive
Cytomegalovirus IgM titer	>4.0, positive	High	≤0.8: no antibody detected; 0.9–1.0: equivocal; ≥1.1: antibody detected
EBV IgG titer	>5.00, positive	High	≤0.90: negative; 0.91–1.09: equivocal; ≥1.10: positive
EBV IgM titer	4.28, positive	High	≤0.90: negative; 0.91–1.09: equivocal; ≥1.10: positive
EBV nuclear antigen antibody titer	>5.00, positive	High	≤0.90: negative; 0.91–1.09: equivocal; ≥1.10: positive
HSV 1 IgG/IgM titer	<0.90	Negative	≤0.90: negative; 0.91–1.09: equivocal; ≥1.10: positive
HSV 2 IgG/IgM titer	<0.90	Negative	≤0.90: negative; 0.91–1.09: equivocal; ≥1.10: positive
HIV-1 DNA, qualitative TMA	NR	NA	NA
Lyme disease antibody screening	2.64	Positive	≤0.90: negative; 0.91–1.09: equivocal; ≥1.10: positive
Lyme disease IgG	Negative	NA	NA
23-kD IgG band	Reactive	NA	NA
41-kD IgG band	Reactive	NA	NA
Lyme disease IgM	Positive	NA	NA
23-kD IgM band	Reactive	NA	NA
39-kD IgM band	Reactive	NA	NA
41-kD IgM band	Reactive	NA	NA
<i>Toxoplasma</i> IgG titer	≤0.90	Negative	≤0.90: negative; 0.91–1.09: equivocal; ≥1.10: positive
<i>Toxoplasma</i> IgM titer	Negative	NA	NA
Uric acid, mg/dL	3.7	Negative	2.5–8.0
VZV IgG titer	3.18, positive	High	≤0.90: negative; 0.91–1.09: equivocal; ≥1.10: positive
VZV IgM titer	2.40, positive	High	≤0.90: negative; 0.91–1.09: equivocal; ≥1.10: positive
<i>Treponema pallidum</i> , total FTA-ABS	NR	NA	NA

Test	Result	Comment	Reference value or range
Lysozyme, µg/mL	10.4	Negative	7.0–15.0
ACE, U/L	80	High	9–67
ANA screening by IFA	Negative	NA	NA
Malaria screening	Negative	NA	NA
CBC			
Leukocytes, × 10 <sup>3</sup> /mm <sup>3</sup>	6.3	NA	4.3–10.3
Erythrocytes, × 10 <sup>6</sup> /mm <sup>3</sup>	3.62	Low	4.40–6.00
Hemoglobin, g/dL	10.8	Low	4.40–6.00
Hematocrit, %	32.0	Low	42.0–52.0
MCV, fL	88.4	NA	82.0–101.0
MCH, pg	29.8	NA	27.0–34.0
MCHC, g/dL	33.7	NA	31.5–36.0
RDW, %	18.0	High	12.1–14.6
Platelet count, × 10 <sup>3</sup> /mm <sup>3</sup>	312	NA	140–440
Mean platelet volume, fL	7.0	Low	7.6–11.6
Neutrophils, %	56.6	NA	43.0–72.0
Lymphocytes, %	39.8	NA	18.0–43.0
Monocytes, %	3.4	Low	4.0–12.0
Eosinophils, %	0.0	NA	NA
Basophils, %	0.2	NA	NA
Absolute no. neutrophils, × 10 <sup>3</sup> /mm <sup>3</sup>	3.57	NA	NA
Absolute no. lymphocytes, × 10 <sup>3</sup> /mm <sup>3</sup>	2.5	NA	NA
Absolute no. monocytes, × 10 <sup>3</sup> /mm <sup>3</sup>	0.2	NA	NA
Absolute no. eosinophils, × 10 <sup>3</sup> /mm <sup>3</sup>	0.0	NA	NA
Absolute no. basophils, × 10 <sup>3</sup> /mm <sup>3</sup>	0.0	NA	NA
Erythrocyte morphology: anisocytosis	1+	NA	NA
Erythrocyte morphology: microcytosis	1+	NA	NA
Erythrocyte morphology: polychromasia	1+	NA	NA
Platelet morphology: large	Present	NA	NA
Platelet estimate	ADQ	NA	NA
PCR (respiratory pathogens)			
Adenovirus	ND	NA	NA
<i>Bordetella pertussis</i>	ND	NA	NA
<i>Chlamydophila pneumoniae</i>	ND	NA	NA
Coronavirus 229E	ND	NA	NA
Coronavirus HKU1	ND	NA	NA
Coronavirus NL63	ND	NA	NA
Coronavirus OC43	ND	NA	NA
Human metapneumovirus	ND	NA	NA
Human rhinovirus/enterovirus	ND	NA	NA
Influenza 2009 virus, H1 subtype	ND	NA	NA
Influenza A virus, H1 subtype	ND	NA	NA
Influenza A virus, H3 subtype	ND	NA	NA
Influenza B virus	ND	NA	NA
<i>Mycoplasma pneumoniae</i>	ND	NA	NA
Parainfluenza virus 1	ND	NA	NA
Parainfluenza virus 2	ND	NA	NA
Parainfluenza virus 3	ND	NA	NA
Parainfluenza virus 4	ND	NA	NA
Respiratory syncytial virus	ND	NA	NA
Protein electrophoresis			
Protein, total, g/dL	7.3	NA	6.1–8.1
Interpretation	Normal pattern	NA	NA
β-globulins, g/dL	0.8	NA	0.8–1.4
α <sub>2</sub> -globulins, g/dL	0.7	NA	0.5–1.0
α <sub>1</sub> -globulins, g/dL	0.3	NA	0.1–0.3
Albumin g/dL, g/dL	4.1	NA	3.5–4.7
γ-globulins, g/dL	1.5	NA	0.6–1.6
BMP			
Sodium, mmol/L	139	NA	135–145
Potassium, mmol/L	4.2	NA	3.5–5.3
Chloride, mmol/L	101	NA	97–110
Carbon dioxide, mmol/L	25	NA	24–32
Anion gap, mg/dL	13	NA	5–15
Glucose, mg/dL	97	NA	70–99
Blood urea nitrogen, mg/dL	12	NA	7–23
Urine creatinine, mg/dL	1.10	NA	0.60–1.30
Glomerular filtration rate, mL/min	>60	NA	>60

Test	Result	Comment	Reference value or range
Calcium (ionized, whole blood) mg/dL	4.6	NA	4.6–5.3

\*ANCA, antineutrophil cytoplasmic antibody; MPO/PR3, myeloperoxidase/proteinase 3; P-ANCA, perinuclear ANCA; NA, not applicable; CRP, C-reactive protein; ESR, erythrocyte sedimentation rate; EBV, Epstein-Barr virus; HSV, herpes simplex virus; TMA, transcription-mediated amplification; NR, not reactive; VZV, varicella zoster virus; FTA-ABS, fluorescent treponemal antibody absorption test; ACE, angiotensin-converting enzyme; ANA, antinuclear antibody; IFA, immunofluorescence assay; CBC, complete blood count; MCV, mean corpuscular volume; MCHC, mean corpuscular hemoglobin concentration; RDW, red blood cell distribution width; ADQ, adequate; ND, not detected; BMP, basic metabolic panel.

**Technical Appendix Table 2.** Repeat laboratory results for possible etiology of uveitis in patient with Ebola virus disease, April 2015\*

Test	Result	Comment	Reference value or range
ANCA screening with MPO/PR3, reflex to ANCA titer	Negative	Negative	NA
Myeloperoxidase antibody titer	<1.0	Negative	<1.0: no antibody detected; ≥1.0: antibody detected
PR3 antibody titer	<1.0	Negative	1.0: no antibody detected; ≥1.0: antibody detected
CRP (January 2015), mg/L	<1.0	Negative	<10
ESR, Westergren, mm/h	11	Negative	0–20
Cytomegalovirus IgG titer	2.78, positive	High	≤0.90: negative; 0.91–1.09: equivocal; ≥1.10: positive
Cytomegalovirus IgM titer	0.7	Negative	≤0.8: no antibody detected; 0.9–1.0 equivocal; ≥1.1: antibody detected
EBV IgG titer	>5.00, positive	High	≤0.90: negative; 0.91–1.09: equivocal; ≥1.10: positive
EBV IgM titer	<0.90	Negative	≤0.90: negative; 0.91–1.09: equivocal; ≥1.10: positive
EBV nuclear antigen IgG titer	>5.00, positive	High	≤0.90: negative; 0.91–1.09: equivocal; ≥1.10: positive
Lyme disease antibody titer	<0.90	Negative	≤0.90: negative; 0.91–1.09: equivocal; ≥1.10: positive
VZV IgG titer	2.62, positive	High	≤0.90: negative; 0.91–1.09: equivocal; ≥1.10: positive
VZV IgM titer	<0.90	Negative	≤0.90: negative; 0.91–1.09: equivocal; ≥1.10: positive

\*ANCA, antineutrophil cytoplasmic antibody; NA, not applicable; MPO/PR3, myeloperoxidase/proteinase 3; CRP, C-reactive protein; ESR, erythrocyte sedimentation rate; EBV, Epstein-Barr virus; VZV, varicella zoster virus.