Abdominal Ultrasound Kidneys

Curved transducer 3-6 MHz

Supine, decubitus or prone

Assess entire organ in longitudinal and transverse

Longitudinal section, transducer aligned with the long axis of the kidney

Transducer rotated 90degrees for transverse section

Deep inspiration to move the kidney downwards to avoid ribs

Adult kidneys 9-13cm

Renal asymmetry is common, 1-1.5cm difference

Right kidney 1-2cm lower due to liver

Oblique lie, black line is orientation of kidney in longitudinal and transverse

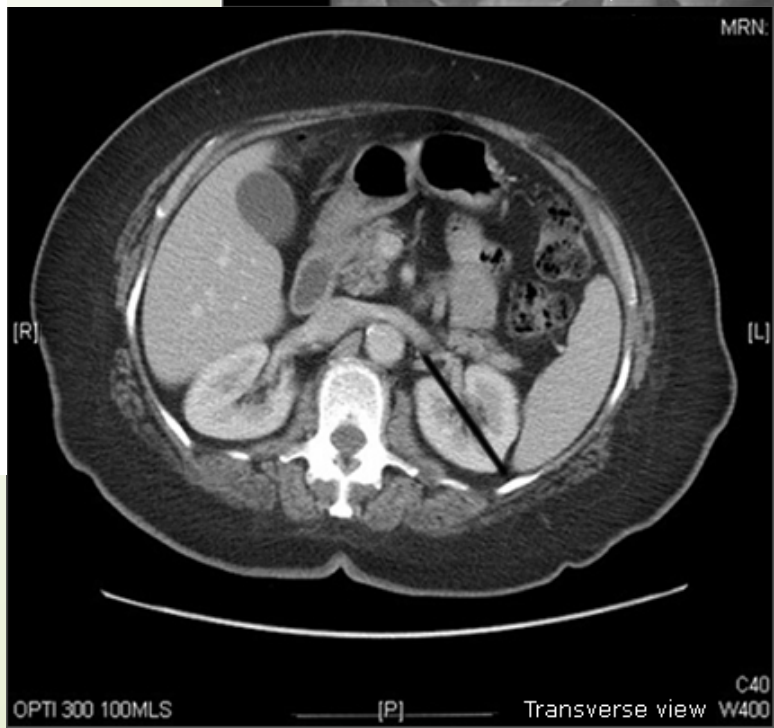

Normal renal cortex echogenicity equal to, or less than the liver

Hyperechoic renal cortex is abnormal

Medullary pyramids have the lowest echogenicity and may appear as hypo- or anechoic

Perinephric fat may be seen, do not mistake for fluid

Longitudinal and transverse normal right kidney

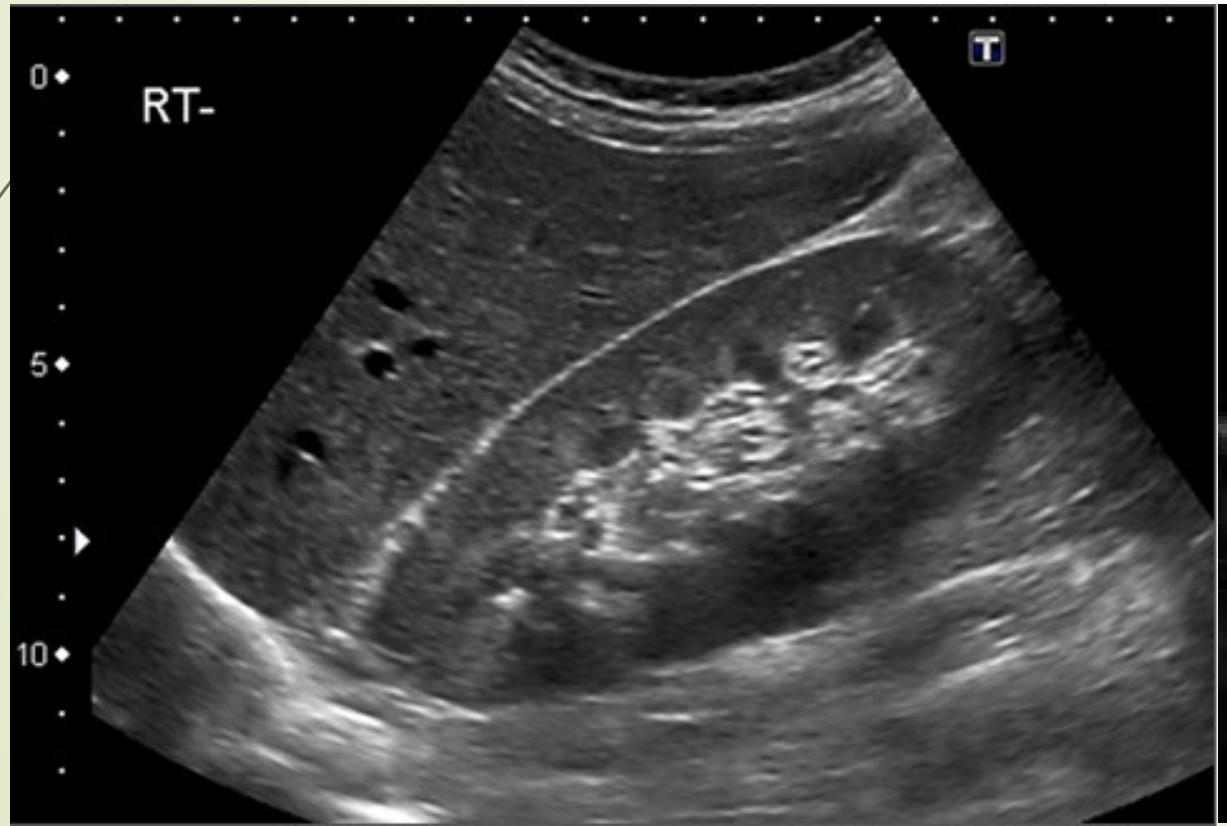

Pelvic/ectopic kidney, if renal fossa is empty, check pelvis

Not always conventional shape, may be mal-rotated and difficult to measure

Congenital abnormalities are common Unilateral renal agenesis, absence of one kidney. Contralateral kidney is usually larger than normal, known as compensatory hypertrophy

Longitudinal of a solitary kidney,(left agenesis) measuring over 13cm

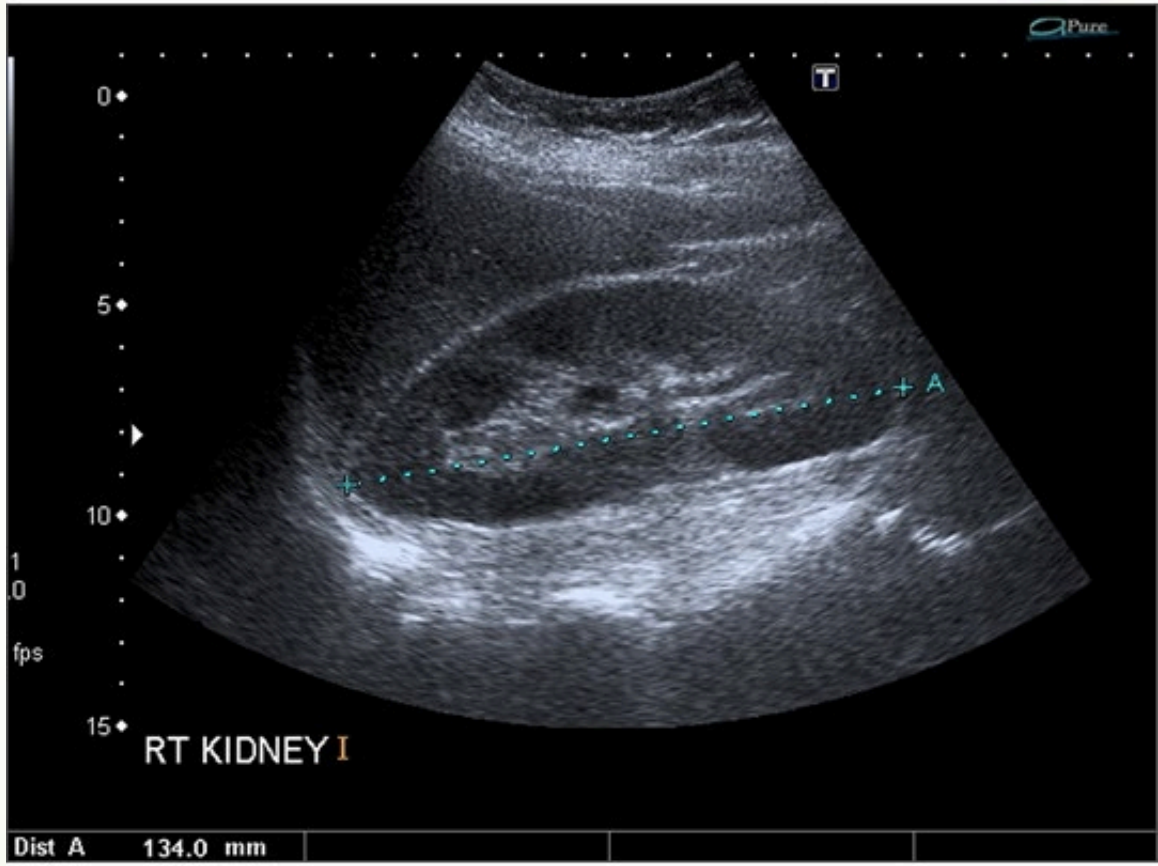

Horseshoe kidneys 1 in 400, lower poles of the kidneys connected by isthmus of renal tissue crossing the midline anterior to aorta and inferior vena cava (IVC)

Easy to miss on ultrasound, suspect when lower poles of both kidneys are difficult to see clearly

Confirm by scanning transversely across the midline to see isthmus.

Image 1 -longitudinal right kidney, poorly visualized lower pole.

Image 2 transverse midline, isthmus anterior to the spine and great vessels

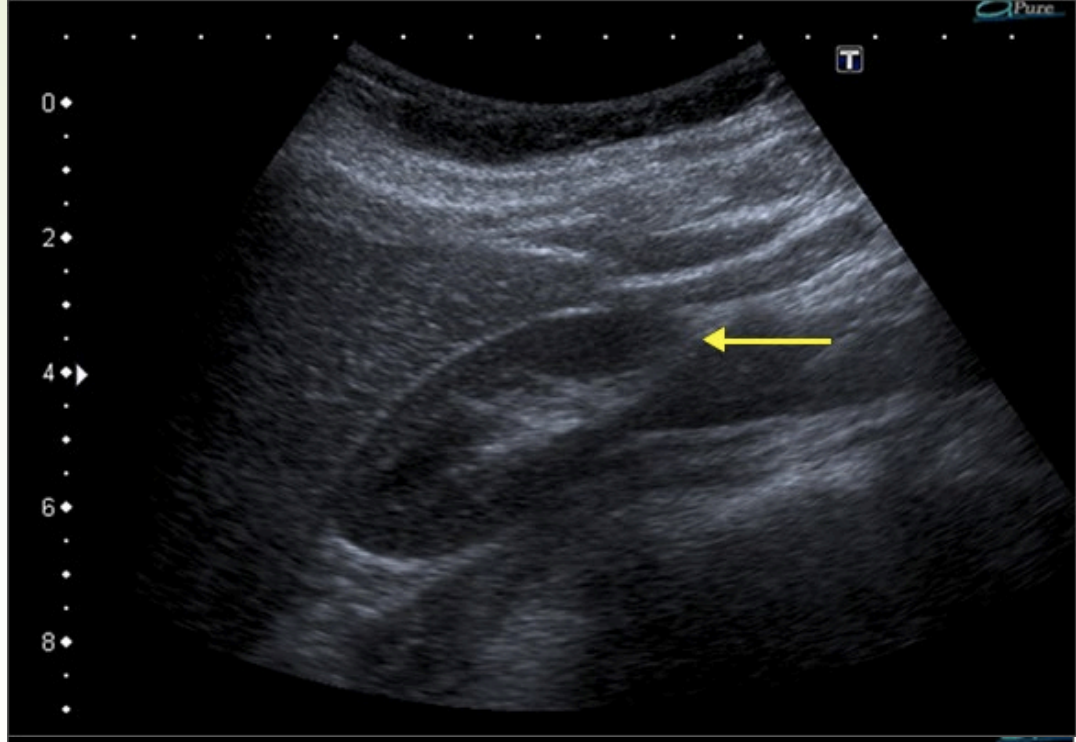

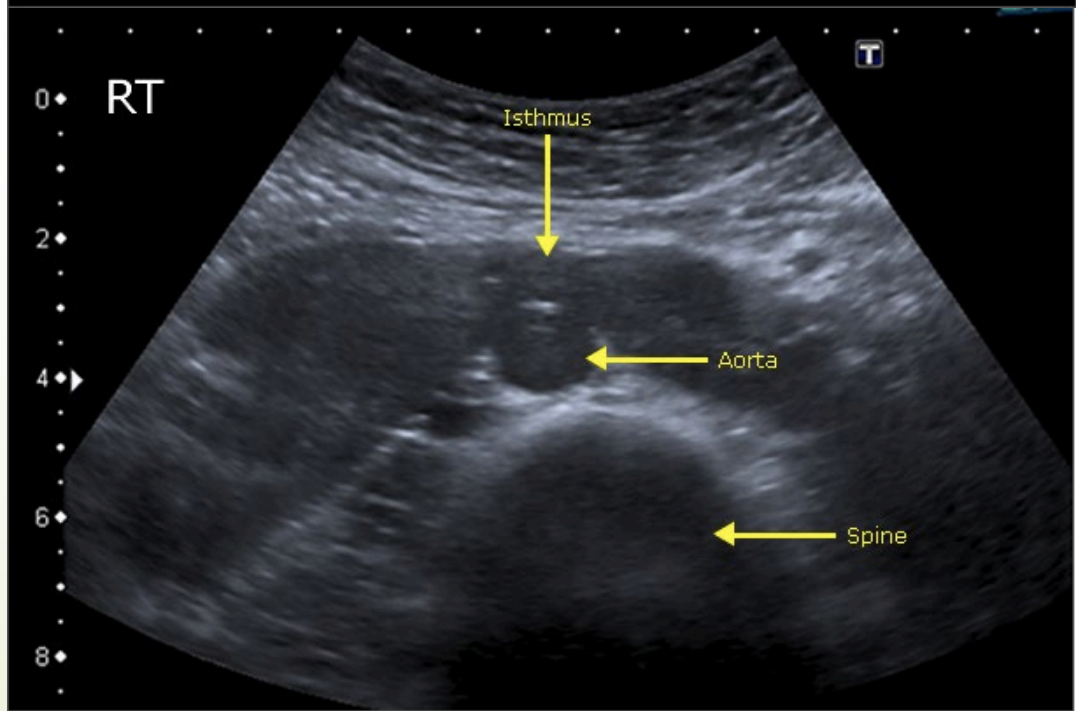

Hypertrophied Column of Bertin

-renal cortex tissue indents deeply into the renal sinus fat

-some more spherical in shape

-no clinical significance

-can mimic renal tumours

-should measure less than 3cm

-isoechoic to cortex

-no effect on the external renal contour

-no vascular pattern disruption

-may contain a renal pyramid

Longitudinal right kidney, hypertrophied column of Bertin. Note apparent mass effect of renal sinus, but renal contour remains normal

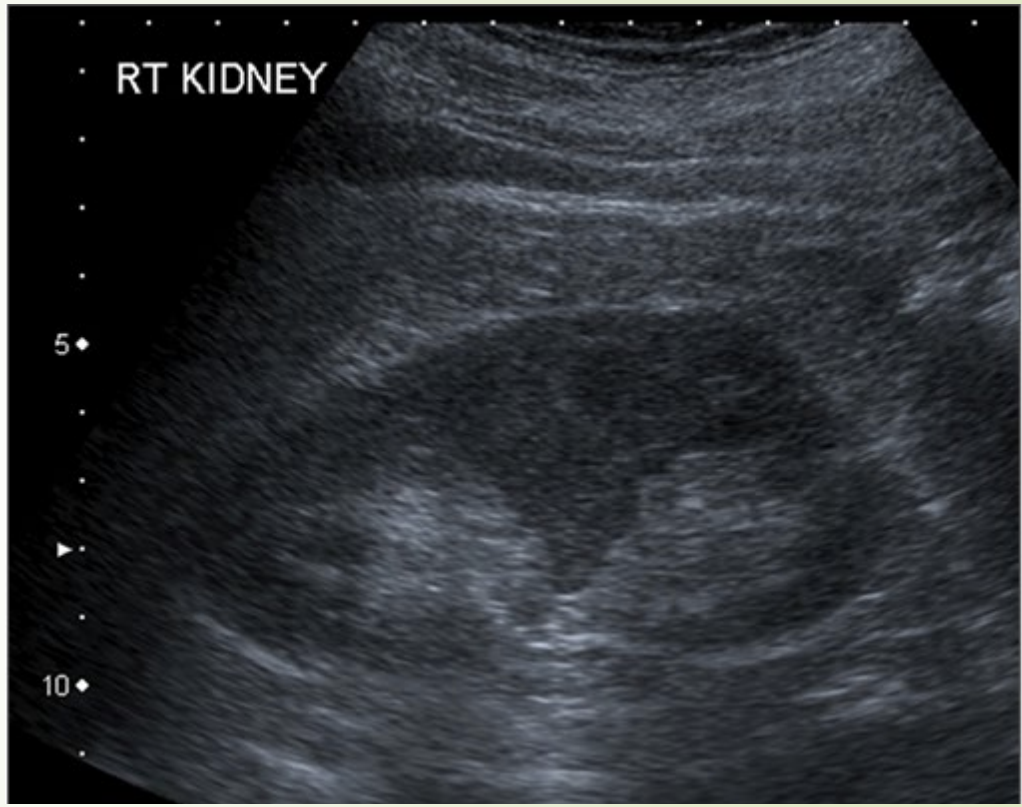

Lobular irregularity of renal outline

-extremely common

-known as persistent fetal lobulation

-no clinical significance

-may mimic renal tumours or scarring.

Dromedary Hump

-common variant of left kidney

-humped or slightly pyramidal shape

-due to extrinsic pressure from the developing spleen

Longitudinal left kidney, prominent cortical outline of a dromedary hump.

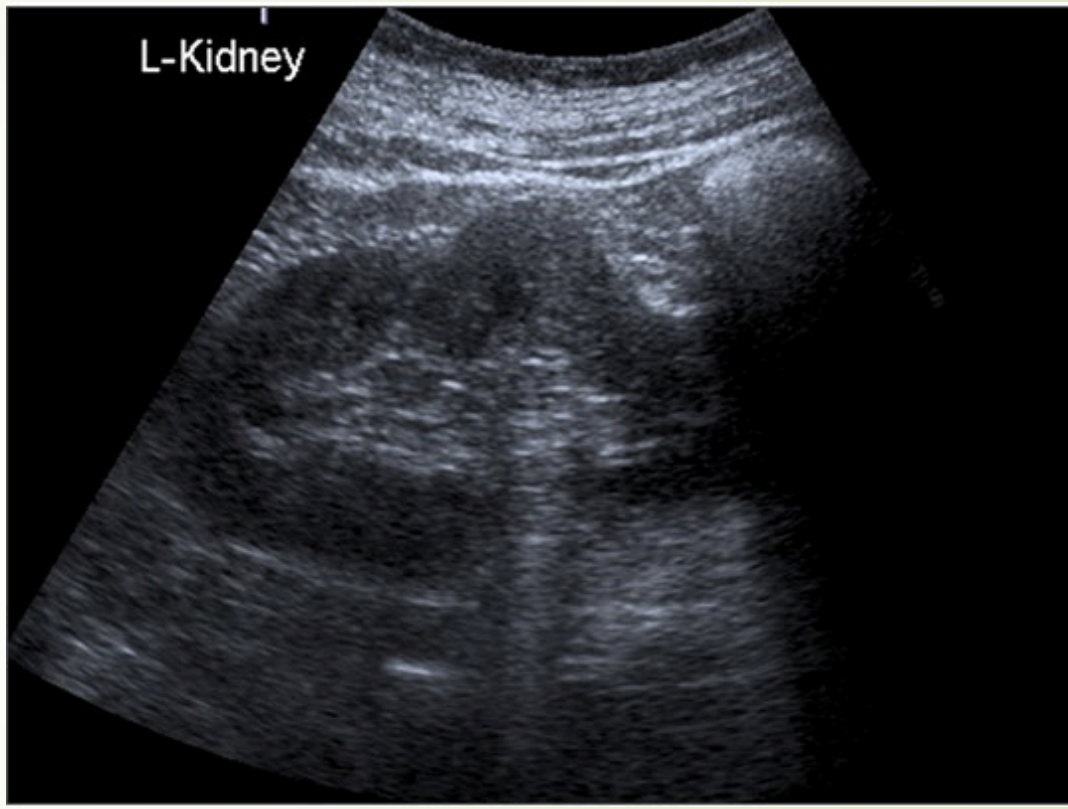

Longitudinal left kidney

Area between calipers (3.15cm) most likely hypertrophied column of Bertin, but recommended that lesions over 3cm have other imaging such as CT

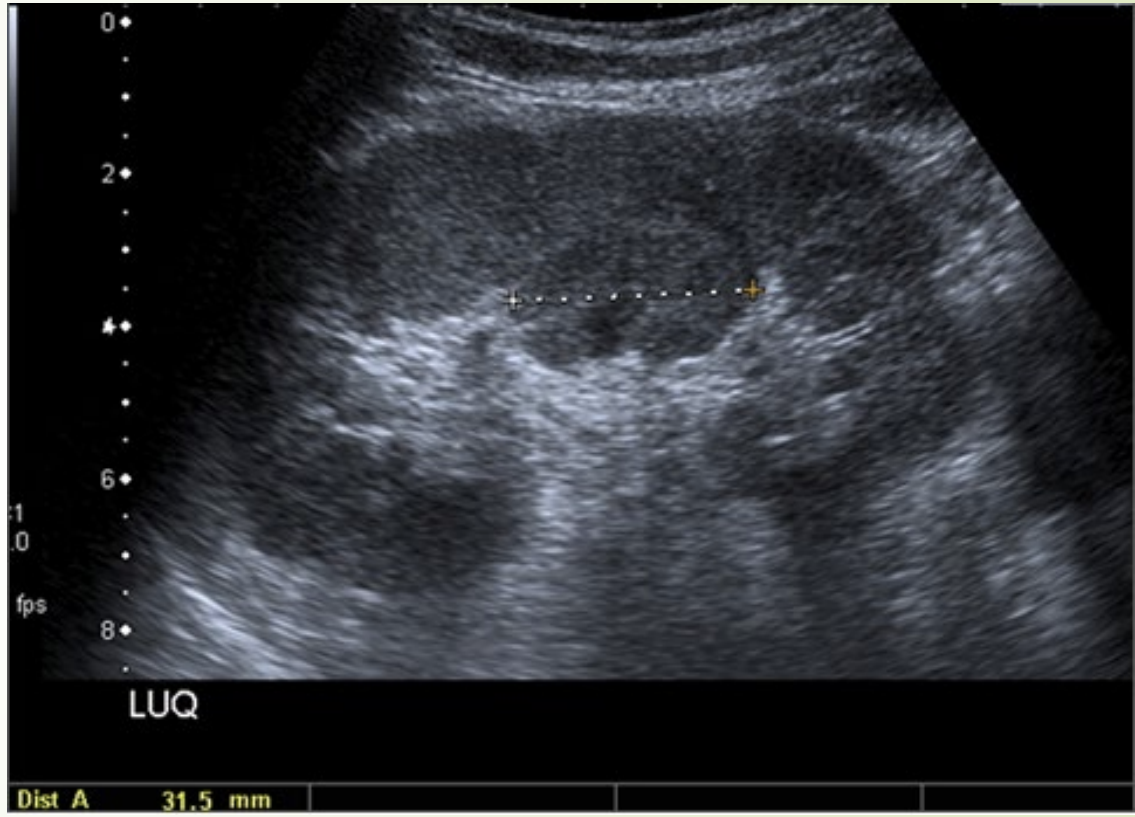

Renal calculi range in size from the very small to very large staghorn calculi.

Image 1 -ultrasound image, staghorn calculus in right kidney.

Image 2 corresponding x-ray

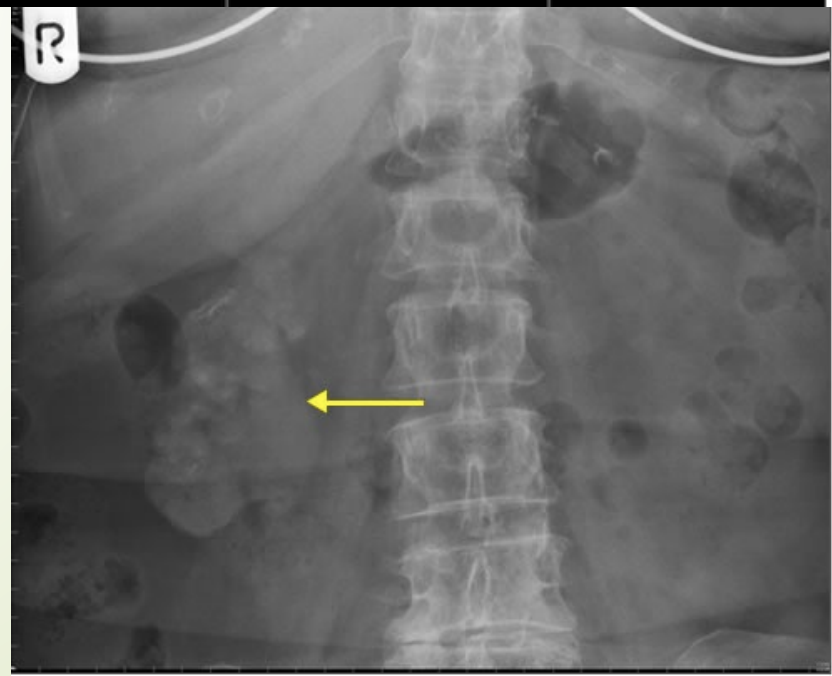

All renal calculi if large enough will cast acoustic shadow (less than 5mm difficult to detect)

Vessel walls at the corticomedullary junction may mimic a stone but will not cast an acoustic shadow in two planes

Calculus will shadow in all planes and angles.

Longitudinal of small calculus in lower pole with acoustic shadow behind it

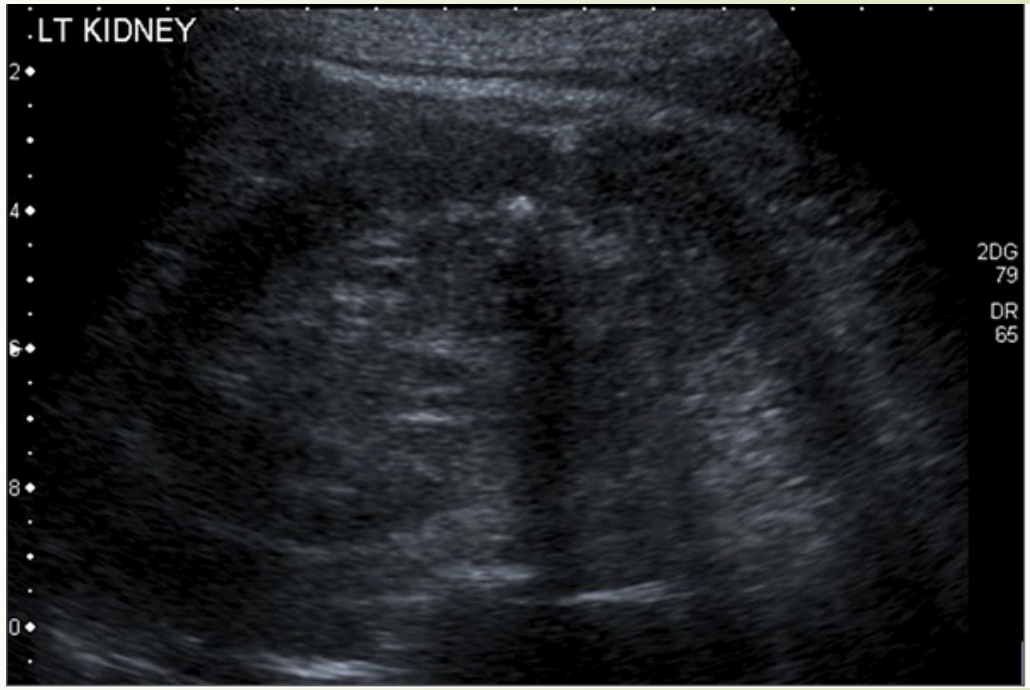

Colour Doppler can detect small stones with twinkle artefact

Longitudinal of small stone in lower pole with twinkle artefact

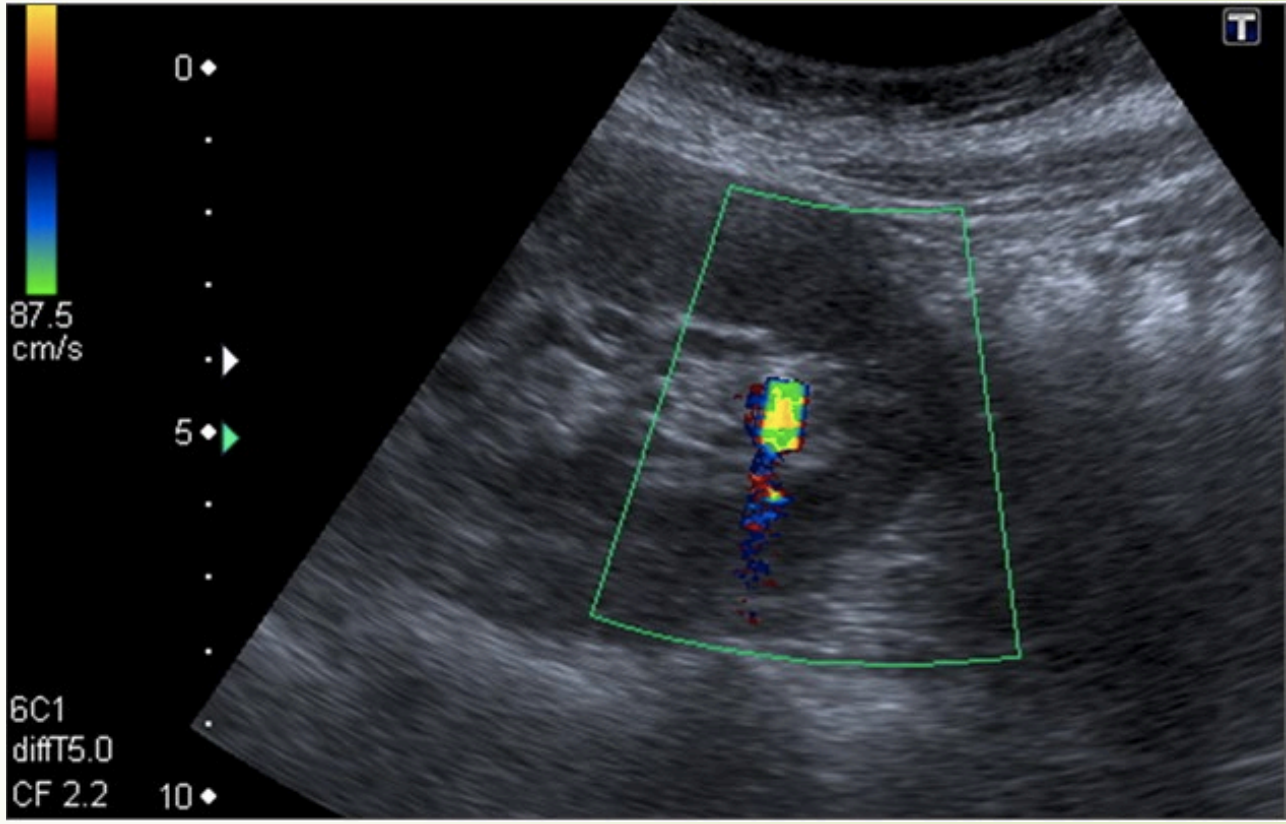

Hydronephrosis

-distension of renal pelvis and calyces with urine

-anechoic fluid

-easy to recognize.

Longitudinal hydronephrosis, mild, moderate, severe

Common causes of hydronephrosis include:

- Urinary tract obstruction
  - Renal stones
  - Abdominal or pelvic tumours
  - Retroperitoneal fibrosis
  - Pelvic inflammatory masses (e.g. diverticular abscess or tubo-ovarian abscess)
  - Endometriosis
  - Transitional cell tumours of the bladder or ureter
  - Bladder outflow obstruction
  - Pregnancy
- Reflux nephropathy
- Post-obstructive dilatation
- Congenital megacalyces

If hydronephrosis assess for:

- Bilateral or unilateral
- Dilated ureters, stone proximal or UVJ
- Distended bladder, urinary retention, post void, does the hydronephrosis resolve postvoid
- Abdominal or pelvic pathology causing urinary obstruction, mass effect

Longitudinal images with calculus in proximal ureter and UVJ

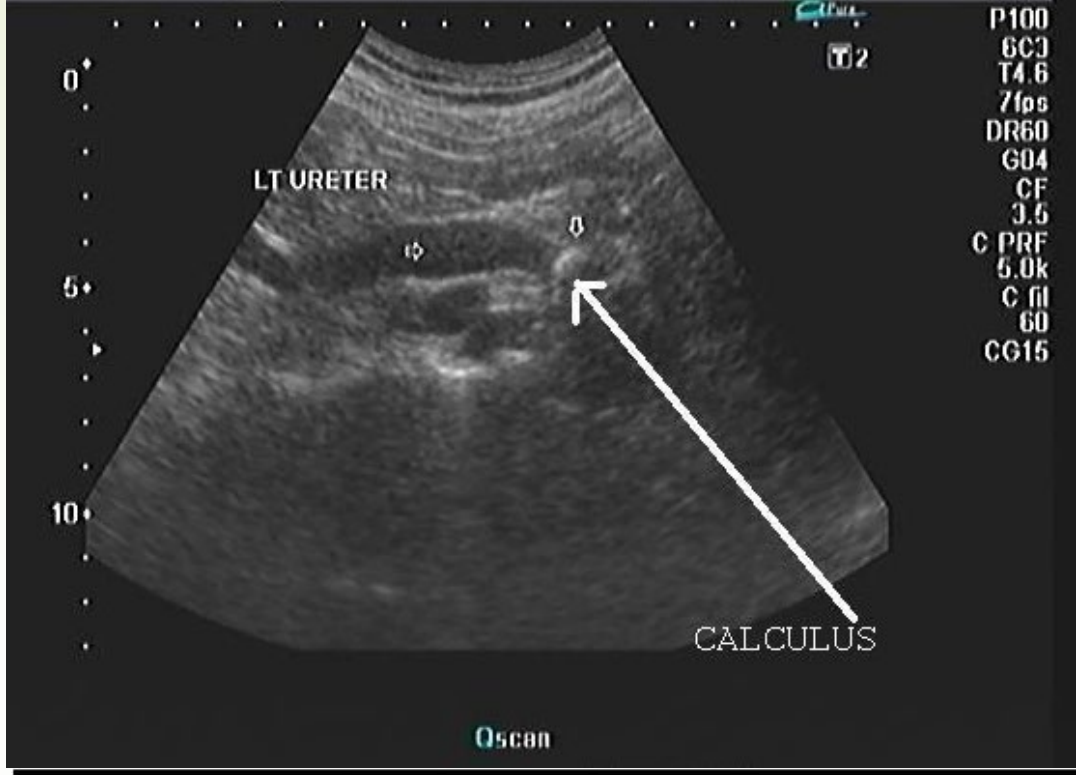

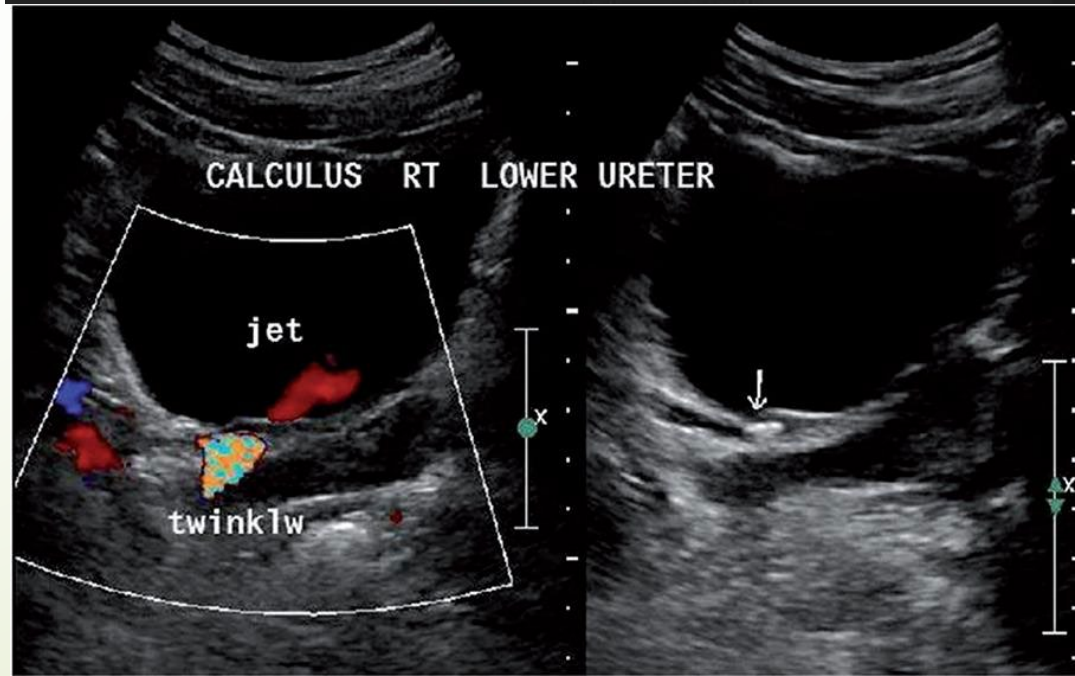

Normal renal cortex

-iso- or hypoechoic to liver

-hypoechoic to spleen.

Increased cortical echogenicity is non-specific finding, implies renal disease

Longitudinal right renal cortex hyperechoic compared to liver

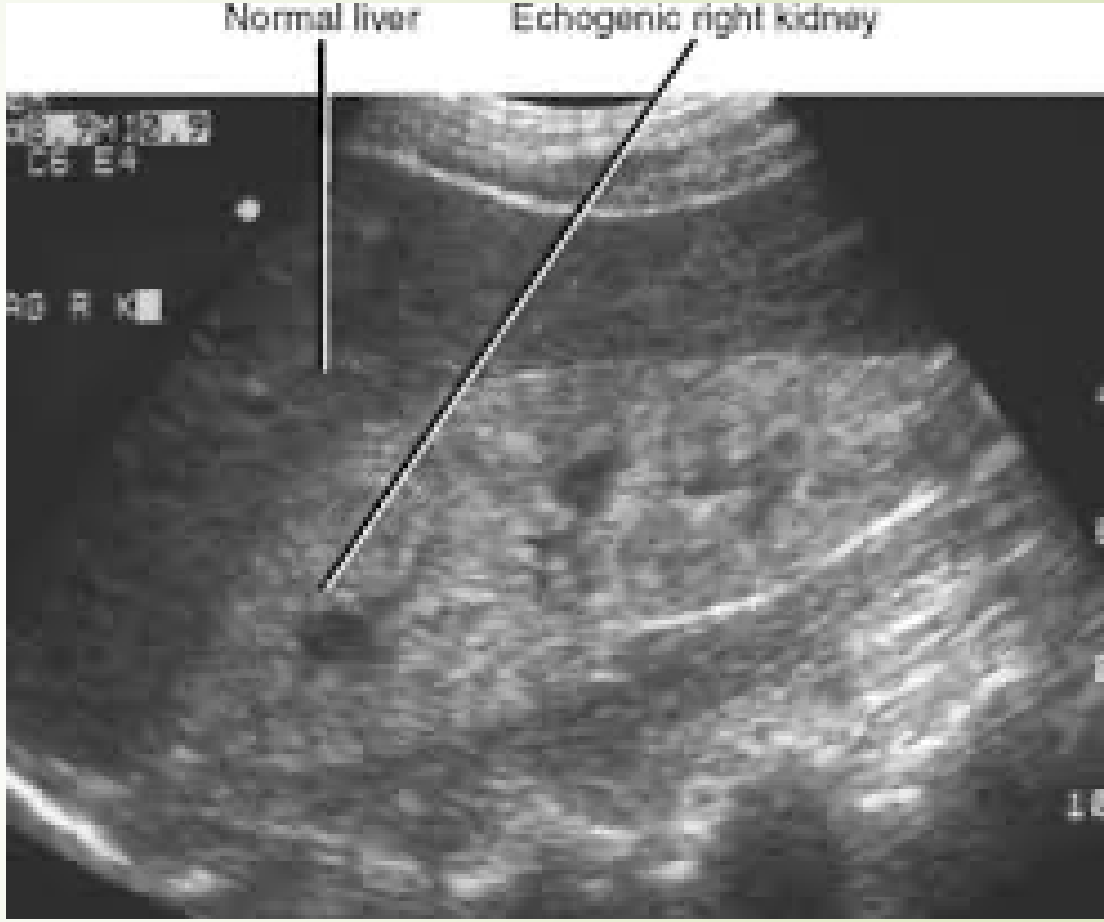

Renal cysts

-more common in older patients

-generally no clinical significance unless polycystic kidney disease

-may arise from renal cortex or renal sinus (parapelvic)

Criteria for simple cyst:

- Anechoic with posterior acoustic enhancement
- No internal septa or solid elements
- Thin imperceptible wall

Longitudinal, small simple cyst with posterior enhancement

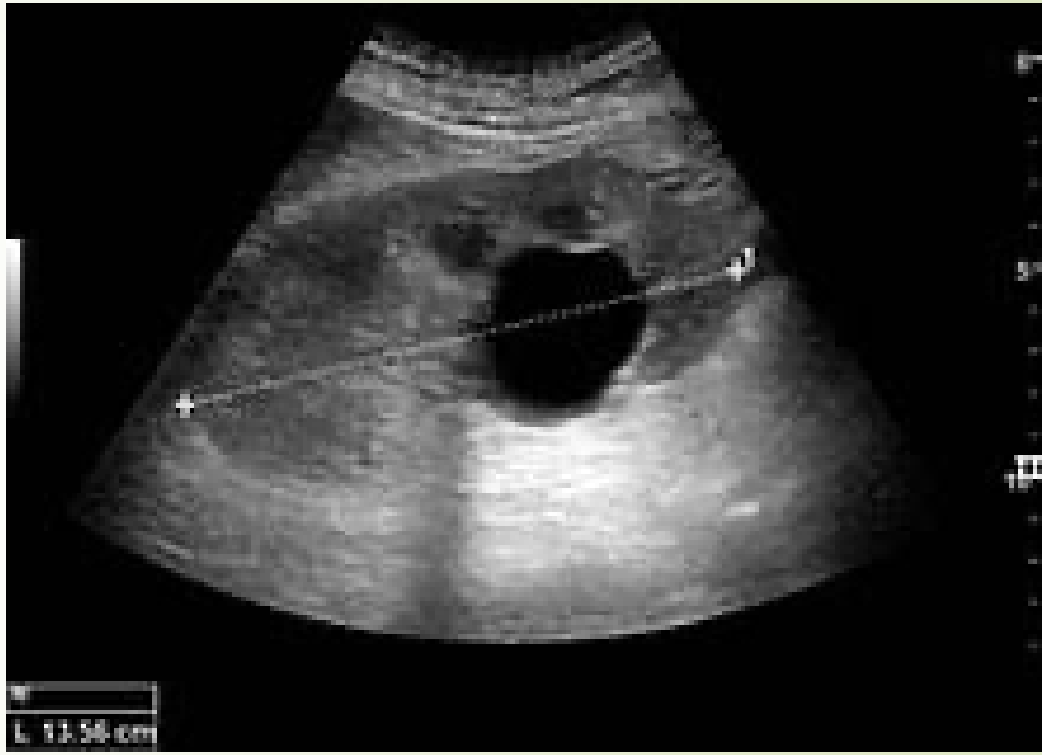

Renal cysts with a single thin septum is acceptable, cysts with more complexity require further imaging to establish the risk of malignancy.

In the septic patient, a renal abscess will be the differential diagnosis.

Longitudinal left kidney, cystic mass, multiple thick septa and solid elements, higher risk of malignancy

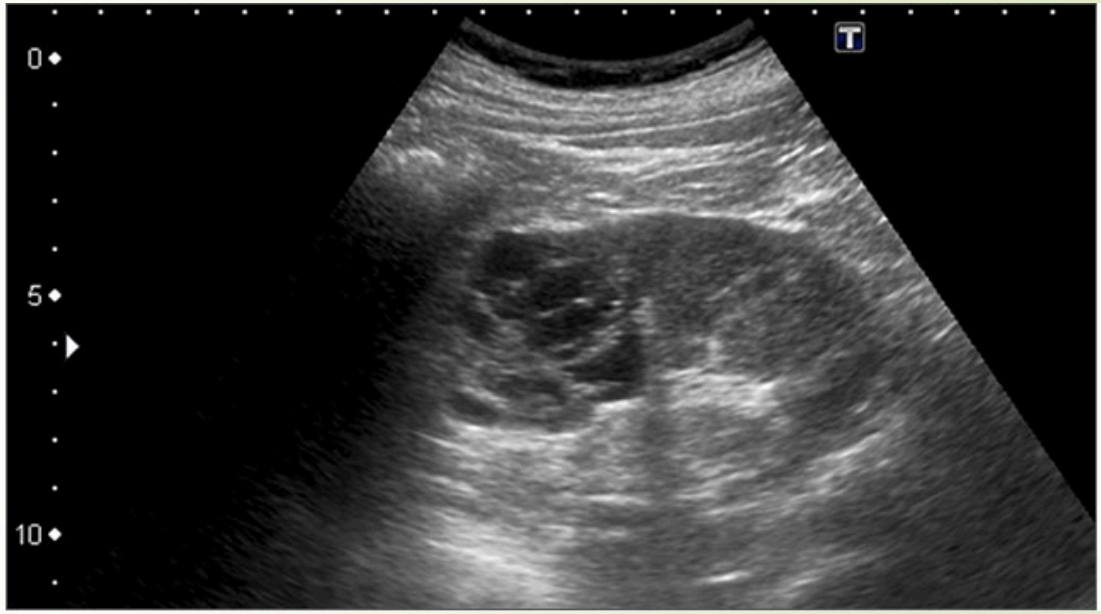

Angiomyolipoma

-most common benign renal tumour

-uniformly hyperechoic

-well-defined

-no internal blood flow

-above 5cm increased risk of hemorrhage which needs urology referral

Image 1 -2 – longitudinal right kidney, with large, uniformly hyperechoic renal lesion

Image 3 - CT shows fat within the lesion, confirming angiomyolipoma.

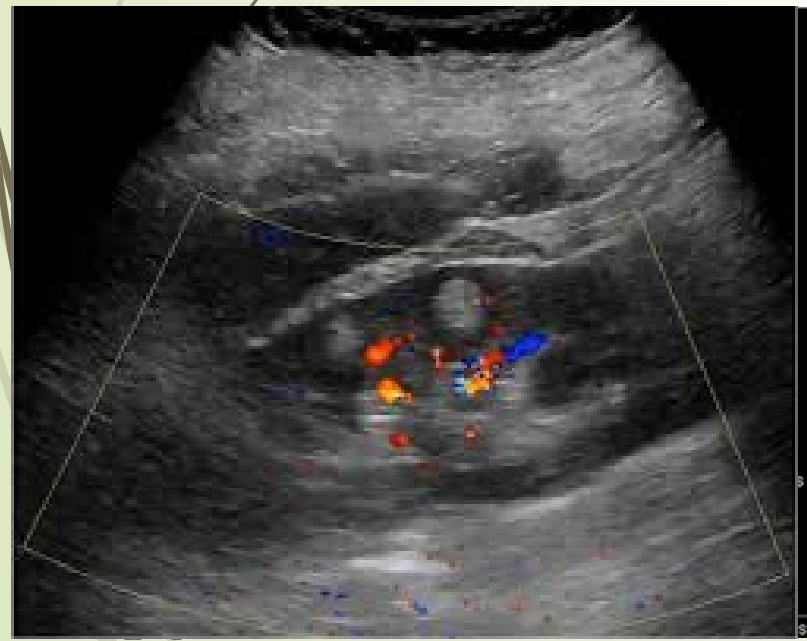

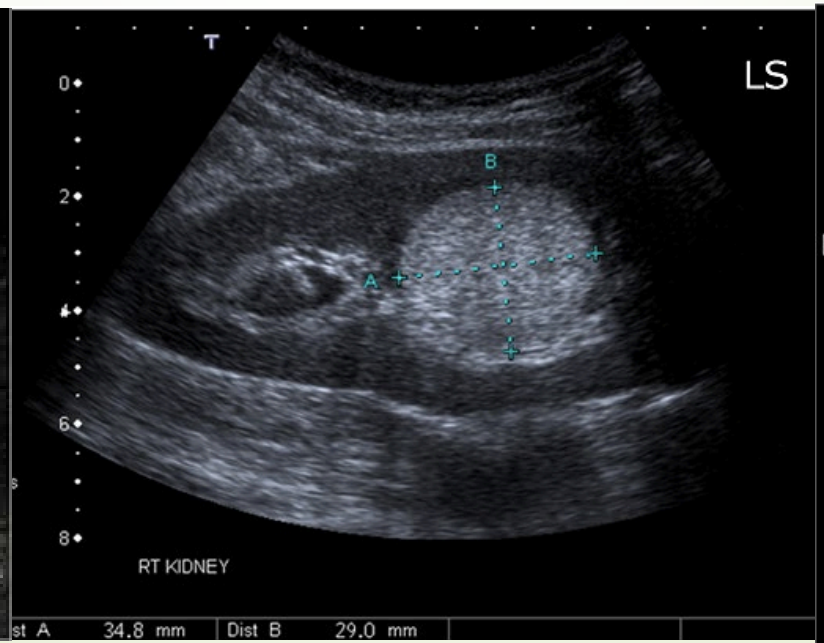

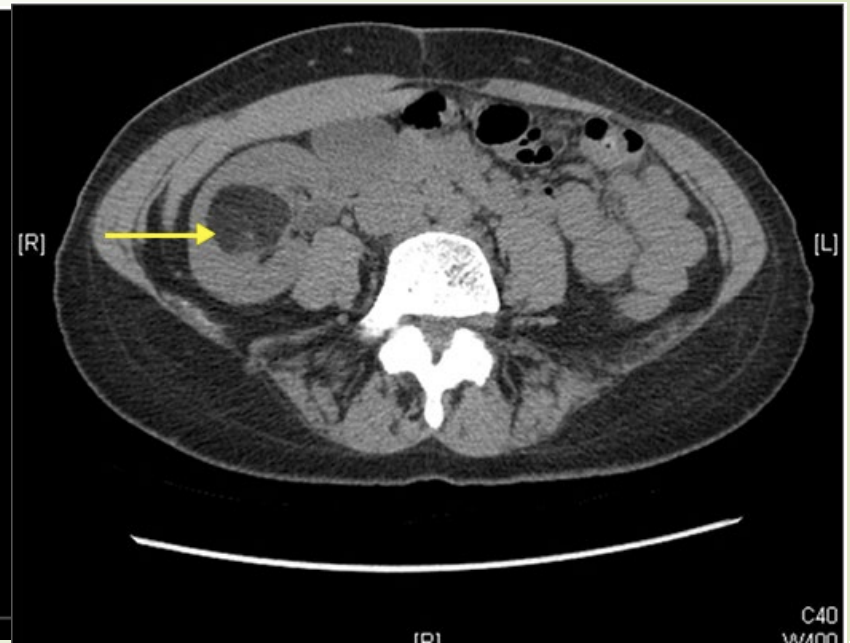

Parapelvic Cysts

-can mimic hydronephrosis

-longitudinal cystic spaces do not interconnect

-no true renal pelvis visible,

Longitudinal right kidney with several parapelvic cysts not hydronephrosis

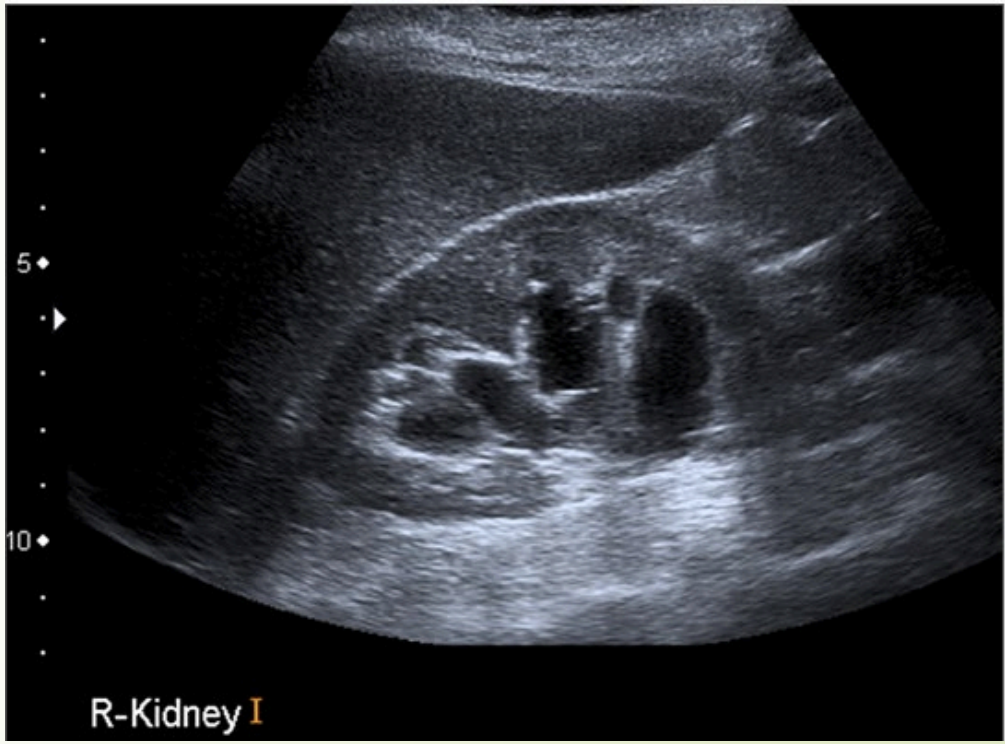

Longitudinal image, fluid within the renal sinus is interconnecting which differentiates from parapelvic cysts. The kidney is hydronephrotic.

Nephrocalcinosis

-multiple hyperechoic foci outside of the renal sinus within the medullary pyramids

-acoustic shadowing confirming calcification

-may occur due to medullary sponge kidney, hyperparathyroidism and renal tubular acidosis

Longitudinal left kidney

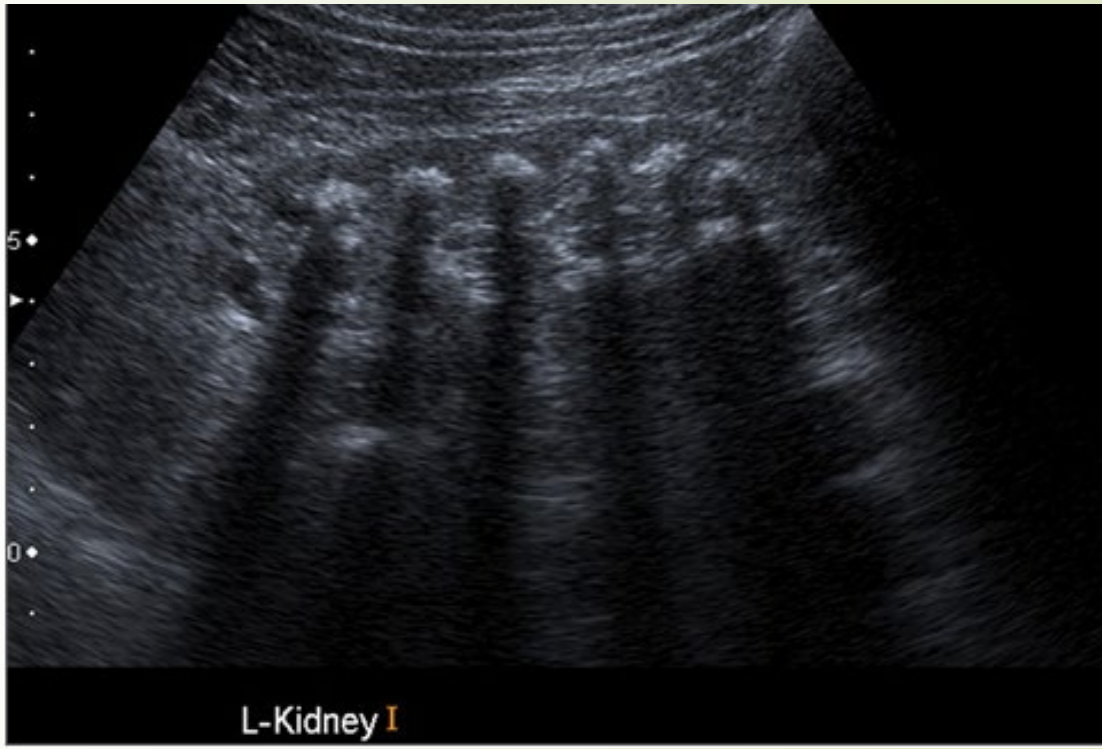

Summary

- Ultrasound is an excellent modality for examining renal anatomy and pathology
- Accurate interpretation of renal ultrasound examinations requires good knowledge of normal anatomical variants
- It is important to understand the limitations of renal ultrasound
- Interpretation is best performed in conjunction with knowledge of the clinical status of the patient and the results of the other laboratory investigations
- The practitioner should be aware of other imaging modalities and how these fit in with overall patient management

Thank You