

# NEUROLOGICAL BULLETIN

FEATURING ARTICLES BY TRAINEES IN NEUROLOGY & NEUROSCIENCE

## Angioedema and Pharyngeal Pain: Unusual Presentation of Internal Carotid Dissection

Eugene Lin and Jane Morris

Departments of Neurology,  
University of Massachusetts Medical School, Worcester, MA (EL)  
Maine Medical Center, Scarborough, ME (JM)

### Introduction

Cervical artery dissections are the most common cause for nonatherosclerotic vasculopathies in young adults who present with stroke.<sup>1</sup> They occur most often between the ages of 35 and 50 years with a peak in the fifth decade of life.<sup>2,3</sup> Community-based studies have shown the annual incidence in the United States to range from 2.5-3.0 per 100,000.<sup>4</sup> The importance of recognizing presentations of carotid artery dissections help to identify and treat patients. Common signs include unilateral head, face, or neck pain with Horner's syndrome, cranial nerve palsies, or pulsatile tinnitus. These may be preceded by minor trauma that is noted upon further history. Here we impart an unusual presentation of internal carotid artery (ICA) dissection mimicking angioedema with unilateral tongue swelling and associated pharyngeal pain.

### Case Report

A 29-year-old gentleman with no significant past medical history had presented to the emergency room (ED) for evaluation after 1

week of symptoms. These first manifested after a strenuous game of basketball and included headache, right-sided neck pain, and sore throat that did not respond to Tylenol or a 4 day treatment of penicillin for a presumptive diagnosis of strep throat at an outside ED. In addition, he had also presented with facial weakness that was diagnosed as Bell's palsy and treated with oral steroids. He soon sought a second visit to the ED due to poor alleviation of his headache and right-sided neck pain and was noted to have anisocoria, which prompted a neurology consultation. He denied any falls or obvious injuries during the basketball game. On physical exam, he was noted to have cranial nerve deficits consisting of right pupil miosis, ptosis, right lip droop (remainder of the facial muscles without weakness), and right sided tongue swelling with deviation (Figure 1). The remainder of his exam including motor and sensory functions was normal. Subsequent imaging studies of computed tomography (CT) and magnetic resonance imaging (MRI) of his head and neck vessels revealed tongue asymmetry and narrowed true lumen of the right internal carotid artery (ICA) beginning at the lower one third and extending to the

---

*Correspondence to* Eugene Lin: [Eugene.lin@umassmemorial.org](mailto:Eugene.lin@umassmemorial.org)

*Keywords:* Carotid artery dissection, angioedema, Horner's syndrome

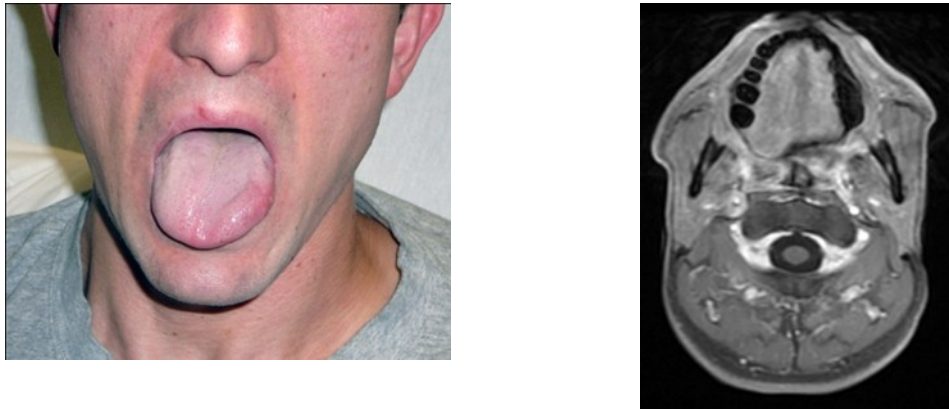

Figure 1 (left): Angioedema of the tongue on the right at presentation.  
Figure 2 (right): Right tongue asymmetry seen on MRI.

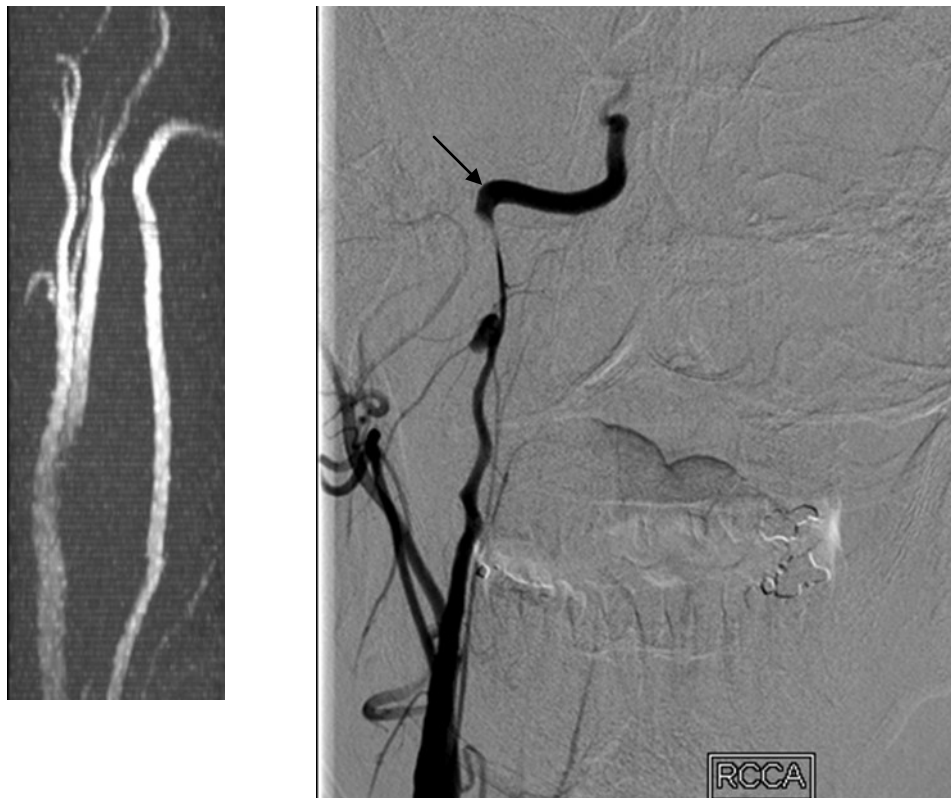

Figure 3 (left): MRA of right ICA dissection.  
Figure 4 (right): Angiogram AP view of right ICA dissection with pseudoaneurysm (arrow)

skull base with noted outpouching of 3 mm x 7 mm (Figures 2 and 3). This was confirmed through 4 vessel angiography, and findings were consistent with ICA dissection with associated pseudoaneurysm formation (Figure 4).

## Discussion

The early identification of ICA dissections is important in preventing further extension through activities such as chiropractic manipulation for neck pain. In addition, anterior circulation ICA dissections can often manifest as cerebral ischemia further underscoring the importance of early diagnosis.<sup>5</sup> Dissections can have intracranial or extracranial involvement with intracranial dissections having more severe symptoms and a less favorable prognosis. Although they can present at all ages, they are commonly noted between the ages of 35 and 50 with peak incidence in the fifth decade without a gender predilection.<sup>2</sup> The causes for ICA dissection in most cases are unclear and can range from extrinsic etiologies such as chiropractic manipulation, trauma, or hypertension to intrinsic causes including fibromuscular dysplasia, Marfan syndrome, cystic medial necrosis, type IV Ehlers-Danlos Syndrome,<sup>6</sup> and elevated homocysteine levels.<sup>7</sup> Infections have also been found to be a potential risk factor, but when adjusted for mechanical stress associated with coughing, sneezing, or vomiting, the decreased odds ratio (1.60, 95% CI 0.67 to 3.80) suggests only a weak association.<sup>8</sup> Our patient did not have any of these risk factors after extensive evaluation, and the only attributable risk factor that was noted was the vigorous basketball game one week prior to his presentation.

Clinical presentations of ICA dissection can vary greatly based on the segment involved. The patient's initial symptoms resulted in a misdiagnosis of strep throat due to com-

plaints of sore throat and tongue swelling with right ear pain. Initial presentation of a dissection with angioedema of the tongue has only been mentioned in one prior case report based on our MEDLINE literature search.<sup>9</sup> The case identified a unique initial presentation of apparent tongue swelling mimicking angioedema in a patient with spontaneous ICA dissection with deviation of the tongue to the side of the dissection. However, our patient had further presenting symptoms noted at the second emergency department visit, including Horner's syndrome,<sup>10</sup> headache, and neck pain that better reflect the usual presentation of a patient with ICA dissection. Other commonly presenting symptoms include scalp tenderness, amaurosis fugax, cranial nerve (CN) palsies, cerebral infarction, and tinnitus. CN palsies are usually associated with ipsilateral extracranial internal carotid dissections and have been found to occur in 12% of patients.<sup>11</sup> If CN IX to XII are involved, then the syndrome is referred to as Collet-Sicard and has been reported with involvement by metastatic cancer.<sup>12</sup> In our case, the likely CN involved was the hypoglossal nerve resulting in ipsilateral deviation of the tongue.

Radiological confirmation to ascertain the etiology of the symptoms was obtained with CT angiography (CTA), MR angiography (MRA), and cerebral angiography. MRA can have up to 95% sensitivity and 99% specificity,<sup>13</sup> but a recent review concluded that there are few recent MRA studies and that newer techniques and resolution for MRA and CTA may increase their sensitivity and specificity.<sup>14</sup> Thus a high clinical index of suspicion along with the appropriate radiological exams can help make the appropriate diagnosis.

Patients found to have extracranial carotid dissections have a prognosis related to whether they develop symptoms of an is-

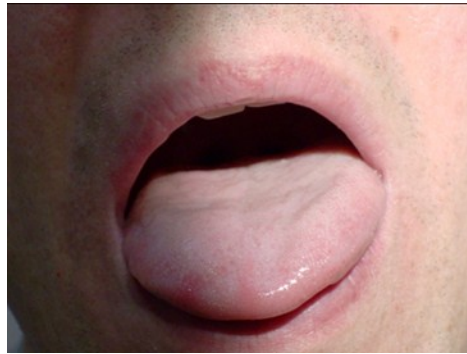

Figure 5: Three month followup of angioedema.

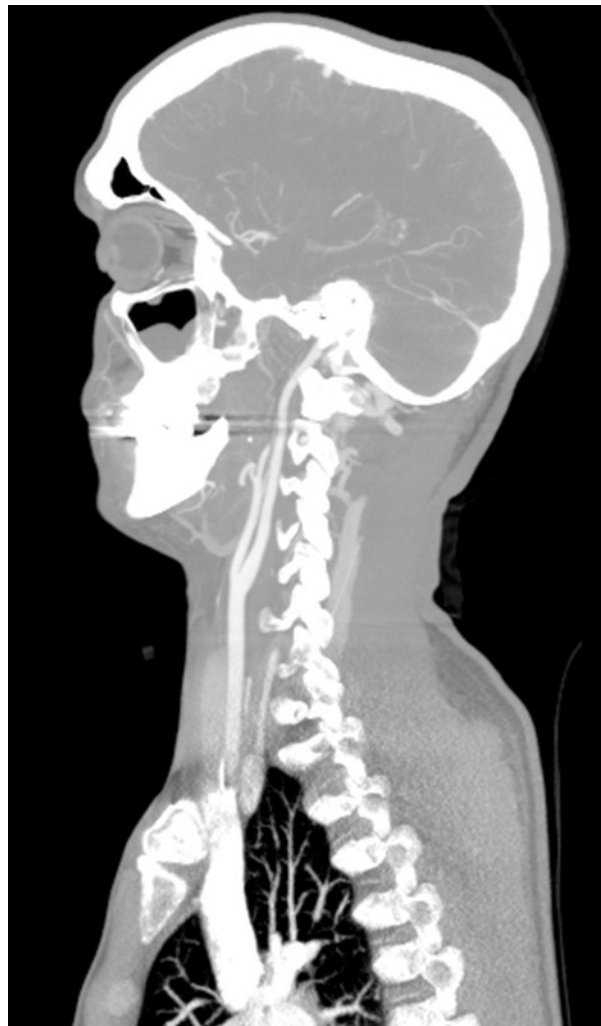

Figure 6: One year follow-up of right carotid artery showing resolving dissection.

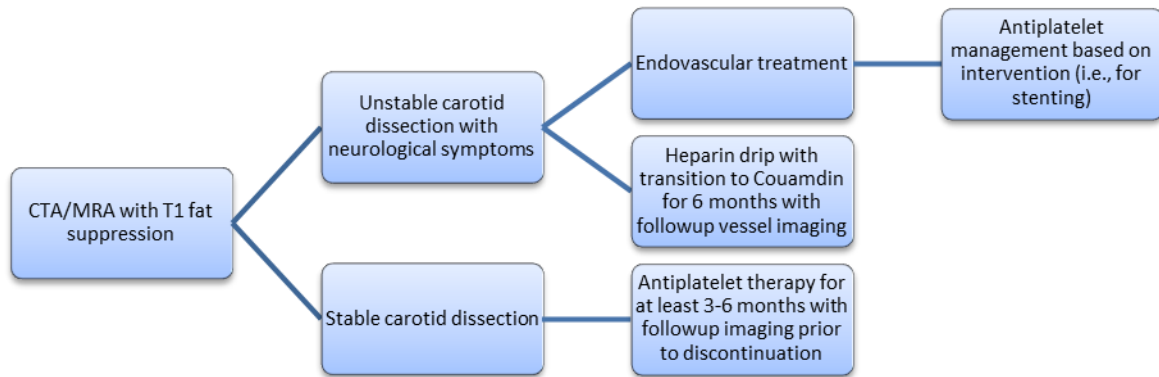


Figure 7: Management of carotid artery dissection

chemic stroke. This is related to the severity of the initial ischemic insult and the extent of collateral circulation. Approximately 90 percent of stenoses eventually resolve and two thirds of occlusions are recanalized, usually within the first two to three months, and are rarely seen after six months. For those who undergo treatment for unstable lesions or have further strokes, endovascular stenting has been shown to have a technical success rate of 99% and a procedural complication rate of 1.3%.<sup>15</sup> However, most dissections of the carotid and vertebral arteries heal spontaneously.<sup>16</sup> Thus, therapy is tailored for prevention of thromboembolic complications, and patients respond well to antithrombotic therapies including aspirin and Coumadin. A Cochrane Database systematic review that considered the studies regarding treatment of carotid artery dissection with antithrombotic drugs concluded that more research was needed but that aspirin is likely to be effective and is probably safer than anticoagulants in such patients.<sup>17</sup> However, for patients

with brain ischemic symptoms, severe narrowing of the arterial lumen, and in those with unstable plaques, heparin drip followed by Coumadin for at least 3 months has been advocated with transition to long-term antiplatelet therapy after 6 months.<sup>18</sup> Continuation of these agents is then determined by the followup imaging performed at 3 months, and with continuation of treatment and repeat imaging at 6 months if there are further signs of ongoing dissection.<sup>19</sup>

## Conclusion

ICA dissection can result in an initial presentation of angioedema with involvement of the hypoglossal nerve that if misdiagnosed allows time for further extension of the dissection and results in further neurological deficits. In our patient, this was seen with the initial diagnosis of strep throat that did not resolve with penicillin, and at subsequent presentation, the patient had progressed to developing Horner's syndrome along with



the associated headache and neck pain. After confirmatory testing, he was treated with aspirin with resolution of his symptoms and healing of the dissection at his final one year follow-up (Figures 5 and 6). His course did not have any complications that required consideration of more aggressive treatment and management (Figure 7).

## References

1. Adams HP Jr, Kappelle LJ, Biller J, et al. Ischemic stroke in young adults. Experience in 329 patients enrolled in the Iowa Registry of stroke in young adults. *Arch Neurol* 1995;52:491-495, <http://dx.doi.org/10.1001/archneur.1995.00540290081021>
2. Schievink WI, Mokri B, O'Fallon WM. Recurrent spontaneous cervical-artery dissection. *N Engl J Med* 1994;330:393-397, <http://dx.doi.org/10.1056/NEJM199402103300604>
3. Bassetti C, Carruzzo A, Sturzenegger M, Tuncdogan E. Recurrence of cervical artery dissection. A prospective study of 81 patients. *Stroke* 1996;27:1804-1807.
4. Schievink WI, Mokri B, Whisnant JP. Internal carotid artery dissection in a community. Rochester, Minnesota, 1987-1992. *Stroke* 1993;24:1678-1680.
5. Huang YC, Chen YF, Wang YH, Tu YK, Jeng JS, Liu HM. Cervicocranial arterial dissection: experience of 73 patients in a single center. *Surg Neurol* 2009;72(Suppl 2):S20-S27, <http://dx.doi.org/10.1016/j.surneu.2008.10.002>
6. Schievink WI, Limburg M, Oorthuys JW, Fleury P, Pope FM. Cerebrovascular disease in Ehlers-Danlos syndrome type IV. *Stroke* 1990;21:626-632.
7. Pezzini A, Del Zotto E, Archetti S, et al. Plasma homocysteine concentration, C677T MTHFR genotype, and 844ins68bp CBS genotype in young adults with spontaneous cervical artery dissection and atherothrombotic stroke. *Stroke* 2002;33:664-669.
8. Grau AJ, Brandt T, Bugge F, et al. Association of cervical artery dissection with recent infection. *Arch Neurol* 1999;56:851-856, <http://dx.doi.org/10-1001/pubs.ArchNeurol.-ISSN-0003-9942-56-7-noc8168>
9. Kaushik S, Abhishek K, Sofi U. Spontaneous dissection of internal carotid artery masquerading as angioedema. *J Gen Intern Med* 2009;24:126-128, <http://dx.doi.org/10.1007/s11606-008-0813-8>
10. Mokri B, Sundt TM Jr, Houser OW. Spontaneous internal carotid dissection, hemicrania, and Horner's syndrome. *Arch Neurol* 1979;36:677-680, <http://dx.doi.org/10.1001/archneur.1979.00500470047008>
11. Mokri B, Silbert PL, Schievink WI, Piepgras DG. Cranial nerve palsy in spontaneous dissection of the extracranial internal carotid artery. *Neurology* 1996;46:356-359.
12. Prashant R, Franks A. Collet-Sicard syndrome--a report and review. *Lancet Oncol* 2003;4:376-377, [http://dx.doi.org/10.1016/S1470-2045\(03\)01097-0](http://dx.doi.org/10.1016/S1470-2045(03)01097-0)
13. Lévy C, Laissy JP, Raveau V, et al. Carotid and vertebral artery dissections: three-dimensional time-of-flight MR angiography and MR imaging versus conventional angiography. *Radiology* 1994;190:97-103.
14. Provenzale JM, Sarikaya B. Comparison of test performance characteristics of MRI, MR angiography, and CT angiography in the diagnosis of carotid and vertebral artery dissection: a review of the medical literature. *AJR Am J Roentgenol* 2009;193:1167-1174, <http://dx.doi.org/10.2214/AJR.08.1688>
15. Pham MH, Rahme RJ, Arnaout O, et al. Endovascular stenting of extracranial carotid and vertebral artery dissections: a systematic review of the literature. *Neu-*

- rosurgery 2011;68:856-866, <http://dx.doi.org/10.1227/NEU.0b013e318209ce03>
16. Schievink WI. Spontaneous dissection of the carotid and vertebral arteries. *N Engl J Med* 2001;344:898-906, <http://dx.doi.org/10.1056/NEJM200103223441206>
  17. Lyrer P, Engelter S. Antithrombotic drugs for carotid artery dissection. *Cochrane Database Syst Rev* 2010;10:CD000255, <http://dx.doi.org/10.1002/14651858.CD000255.pub2>
  18. Caplan LR. Dissections of brain-supplying arteries. *Nat Clin Pract Neurol* 2008;4:34-42, <http://dx.doi.org/10.1038/ncpneuro0683>
  19. Furie KL, Kasner SE, Adams RJ, et al. Guidelines for the prevention of stroke in patients with stroke or transient ischemic attack: a guideline for healthcare professionals from the american heart association/american stroke association. *Stroke* 2011;42:227-276, <http://dx.doi.org/10.1161/STR.0b013e3181f7d043>

*Disclosure:* the authors report no conflicts of interest.

All content in *Neurological Bulletin*, unless otherwise noted, is licensed under a Creative Commons Attribution-Noncommercial-Share Alike License <http://creativecommons.org/licenses/by-nc-sa/3.0/> (ISSN 1942-4043)