University of Massachusetts Medical School
eScholarship@UMMS

Anesthesiology Publications and Presentations | Anesthesiology

3-24-2012

Paraplegia Following Pneumonectomy and Descending Thoracic Aorta Mass Resection

Layla Fakhrzadeh
University of Massachusetts Medical School, Layla.Fakhrzadeh@umassmemorial.org

Elifce Cosar
University of Massachusetts Medical School, Elifce.Cosar@umassmemorial.org

Christian Mueller
University of Massachusetts Medical School, Christian.Mueller@umassmemorial.org

See next page for additional authors

Follow this and additional works at: http://escholarship.umassmed.edu/anesthesiology_pubs

Part of the Anesthesiology Commons

Repository Citation
Fakhrzadeh, Layla; Cosar, Elifce; Mueller, Christian; and Watson, Nicholas C., "Paraplegia Following Pneumonectomy and Descending Thoracic Aorta Mass Resection" (2012). *Anesthesiology Publications and Presentations.* Paper 119.
http://escholarship.umassmed.edu/anesthesiology_pubs/119

This material is brought to you by eScholarship@UMMS. It has been accepted for inclusion in Anesthesiology Publications and Presentations by an authorized administrator of eScholarship@UMMS. For more information, please contact Lisa.Palmer@umassmed.edu.

Paraplegia Following Pneumonectomy and Descending Thoracic Aorta Mass Resection

Authors
Layla Fakhrzadeh, Elifce Cosar, Christian Mueller, and Nicholas C. Watson

Comments
Poster presentation at the New England Anesthesia Resident Conference, held on March 24, 2012 in Burlington, VT.

This poster is available at eScholarship@UMMS: http://escholarship.umassmed.edu/anesthesiology_pubs/119

Paraplegia Following Pneumonectomy and Descending Thoracic Aorta Mass Resection

Layla Fakhrzadeh M.D., Elifce Cosar M.D, Christian Mueller M.D., Nicholas C. Watson M.D.
Department of Anesthesiology, University of Massachusetts Medical School, Worcester, MA

Background

We present a case of paraplegia following an *en bloc* resection of a lung mass with thoracic aorta involvement. This complex case poses the opportunity to discuss several perioperative issues:

Fluid management for pneumonectomy:
Pneumonectomy has a high 30-day mortality rate, with incidences reaching 25%.[1] Acute lung injury (ALI) is a major predictor of mortality in pneumonectomy.[1] Clinical data suggest that IV fluids >4L within the first 24 hours can contribute to the development of ALI.[2] As a result, conservative fluid management is recommended.

Fluid management for thoracic aorta cross-clamping:
End-organ ischemia in the setting of aortic cross clamping is minimized by adequate circulating volume and perfusion pressure, which are maintained by administration of ample IV fluids.

Spinal cord ischemia (SCI): SCI is a devastating complication of surgical repair of the thoracic aorta. The incidence of SCI with surgical repair of the thoracic aorta has been reported to be as high as 14%, and thoracotomy has an estimated SCI incidence of 0.08%.[3,4] SCI may present with lower extremity weakness ranging from paraparesis to paraplegia. Moreover, clinical onset of SCI may be immediate or as late as months after the surgery. Prevention of SCI and neurological deficit is not only important in ensuring a better quality of life but also in improving the survival rate.[5,6]

Spinal Cord Ischemia Prevention & Management

Spinal Cord Ischemic Insult	Intervention	Example
Aortic Cross Clamp	Improvement of spinal cord perfusion pressure	Minimize aortic clamp time , increase MAP, Distal aortic perfusion, Reimplantation of intercostals arteries, CSF Drainage
↓	Suppression of spinal cord metabolism	Moderate passive hypothermia (32 to 34°C), profound hypothermic circulatory arrest (14-18°C), infusion of cold saline into the intrathecal space
↓Spinal Artery Perfusion	Pharmacologic neuro-protection of spinal cord	Methylprednisolone, mannitol, naloxone, intrathecal papaverine
↑CSF Pressure	Prevention of steal from collateral arterial network during aortic cross clamping and opening of aorta	Ligation of back-bleeding intercostals arteries, prevention of pharmacologically induced arteriovenous shunting which occurs from use of drugs such as nitroprusside
↓	Early detection and intervention of SCI	Intraoperative monitoring of somatosensory evoked potentials and motor evoked potentials
Spinal Cord Ischemia		

Peri-Operative Timeline

TIME

•First Operation: Flexible bronchoscopy, mediastinoscopy, left-thoracotomy; mass noted to be adherent to descending thoracic aorta; Procedure aborted.

•Second Operation: *En bloc* resection of lung mass with left pneumonectomy, resection of 3cm of descending thoracic aorta and interposition grafting. GETA, thoracic epidural. Aortic cross clamp time = 30 minutes; Operative duration of 8 hours; IVF:1800 mL crystalloid and 200 mL colloid; UO: 260 mL, EBL:700 mL.

•Upon emergence from anesthesia: **Bilateral lower extremity paraplegia** with intact sensation. SCI most likely diagnosis; secondary diagnosis of neuraxial hematoma and overdosed epidural catheter. CSF drain placed, 10 mL CSF removed, patient immediately able to flex bilateral hips 2/5, PF/DF normal.

POD	Neurologic	Pulmonary	Renal
0	•Hourly neurological exams •Phenylephrine gtt for MAP goal > 100 mmHg •CSFD max 10 ml/hr for CSF Pressure > 10 mmHg	•Face mask 50% •Thoracic epidural •IS	•Strict I&O's •Albumin boluses for oliguria
1-2	•Exam unchanged •Norepinephrine gtt for MAP goal > 100 mmHg •CSFD hourly limit removed and set to drain for CSF pressure > 10 mmHg	•Nasal Cannula 4 LPM •Thoracic epidural •IS	•POD 2: FENa =0.5 •Albumin boluses for oliguria
3-4	•Exam unchanged •Norepinephrine gtt for MAP goal > 90 mmHg •CSFD capped on POD4	•Face Mask 40 % •Thoracic epidural •IS	•POD 2: Non-oliguric ATN, multiple muddy brown cast under microscopy •Albumin boluses for oliguria
5-6	•Exam unchanged •D/C norepinephrine on POD 5 •CSFD removed on POD 5 •MRI thoracic-lumbar spine on POD 6 concerning for thoracic cord infarct/edema	•Nasal Cannula 2-3 LPM •D/C Epidural POD 5 •IS	•ATN •See fig 2.
7-D/C	•Exam unchanged •Discharged to Rehab on POD 10	•RA •IS, able to generate 1000 ml	•ATN •See fig 2.
Follow –Up visit	•Able to take a few steps with the aid of a walker	•Saturating 96% on RA	Creatinine=0.90

Figure 1. CXR prior to 2nd operation. Note left peri-hilar mass.

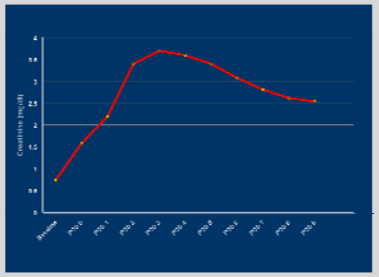

Figure 2. Creatinine trend over peri-operative period.

Discussion

The major intra-operative challenge of this case was the conflicting goals in fluid management for concomitant pneumonectomy and thoracic aorta resection. A conservative approach was taken to fluid management. Although it is difficult to be certain, low-normal intravascular volume and hypotension around the time of aortic clamping and release may have contributed to renal injury and SCI. Conversely, the patient's favorable post-operative pulmonary function may have been attributable, at least in part, to the conservative fluid strategy.

Continued fluid management decisions in the setting of recent pneumonectomy *and* acute kidney injury posed a post-operative challenge. The incidence of renal failure related to thoracic aorta surgery is as high as 18%.[1,7] Indeed, this patient developed post-operative ATN. Intravascular volume maintenance is thought to reduce the risk of kidney injury. In the ICU the patient was given little maintenance IV fluids and intermittent post-operative oliguria was treated with colloid boluses in order to strike a balance between conservative fluid management for optimal pulmonary function and aggressive fluid administration aimed at minimizing any further renal injury. Urine output was maintained and renal function returned without need for dialysis.

The incidence of SCI with surgical repair of the thoracic aorta may be up to 14%.[3] Maintenance of adequate mean arterial pressure, and thus SC perfusion pressure, is paramount in limiting SCI. Typically, first-line management for maintenance of MAP is fluid administration, then vasopressors. As discussed above, aggressive IV fluids were avoided; thus, vasopressors were used for elevated blood pressure goals. Furthermore, we chose CSF drainage for additional SCI treatment as this combination was felt to be the most evidence-based approach of the SCI therapies described in the literature.

References

1. Svensson L, *et al.* Experience with 1509 patients undergoing thoracoabdominal operations. J Vasc Surg. 1993; 17:357-70
2. Licker M *et al.* Risk factors for acute lung injury after thoracic surgery for lung cancer. Anesth and Analg. 2003;97:1558 –65)
3. Subramaniam K, *et al.* Spinal cord protection strategies. *Anesthesia and Perioperative Care for Aortic Surgery.* 2011; 239-256.
4. Attar S, *et al*. Paraplegia after thoracotomy: Report of five cases and review of the literature. *Annals of Thoracic Surgery*. 1995;59:1410-1416.
5. Weigang E, *et al*. Perioperative management to improve neurologic outcome in thoracic or thoracoabdominal aortic stent-grafting. *Annals of Thoracic Surgery.* 2006;82:1679-1687
6. Coselli J, *et al.* Cerebrospinal fluid drainage reduces paraplegia after thoracoabdominal aortic aneurysm repair: Results of randomized clinical trial. *J Vasc Surg.* 2002;35:631-9
7. Kashyap V, *et al*. Renal failure after thoracoabdominal aortic surgery. *J Vascular Surg.* 1997; 26(6):949-55

Abbreviations

ALI, Acute Lung Injury; ATN, Acute Tubular Necrosis; CSFD, Cerebral Spinal Fluid Drain; CXR, Chest X-Ray; DAP, Distal Aortic Perfusion; D/C, Discharge/Discontinue; EBL,Estimated Blood Loss; FE_{Na}, Fractional Sodium Excretion; GETA, General Endotracheal Anesthesia; Gtt, Drip; I&O, In and Out; IS, Incentive Spirometry; LA, Local Anesthetic; LE, Lower Extremity; LPM, Liter Per Minute;MAP, Mean Arterial Pressure; PF/DF, Plantar Flexion/Dorsiflexion; POD, Post-Operative Day; SC, Spinal Cord; SCI, Spinal Cord Ischemia; UO, Urine Output