

2-15-2010

Management of type II superior labrum anterior posterior lesions: a review of the literature

Xinning Li

University of Massachusetts Medical School, xinning.li@gmail.com

Timothy J. Lin

University of Massachusetts Medical School, Timothy.Lin@umassmed.edu

Marcus Jager

Heinrich-Heine-University

See next page for additional authors

Follow this and additional works at: http://escholarship.umassmed.edu/ortho_pp



Part of the [Orthopedics Commons](#), and the [Rehabilitation and Therapy Commons](#)

Repository Citation

Li, Xinning; Lin, Timothy J.; Jager, Marcus; Price, Mark D.; Deangelis, Nicola; Busconi, Brian D.; and Brown, Michael A., "Management of type II superior labrum anterior posterior lesions: a review of the literature" (2010). *Orthopedics and Physical Rehabilitation Publications and Presentations*. 74.

http://escholarship.umassmed.edu/ortho_pp/74

This material is brought to you by eScholarship@UMMS. It has been accepted for inclusion in Orthopedics and Physical Rehabilitation Publications and Presentations by an authorized administrator of eScholarship@UMMS. For more information, please contact Lisa.Palmer@umassmed.edu.

Management of type II superior labrum anterior posterior lesions: a review of the literature

Authors

Xinning Li, Timothy J. Lin, Marcus Jager, Mark D. Price, Nicola Deangelis, Brian D. Busconi, and Michael A. Brown

Rights and Permissions

Citation: Li X, Lin T, Jager M, Price MD, DeAngelis N, Busconi BD, Brown M. Management of type II superior labrum anterior posterior lesions: a review of the literature. *Orthopedic Reviews* 2010; 2:e6. DOI: 10.4081/or.2010.e6. ©Copyright Xinning Li et al., 2010. Licensee PAGEPress, Italy. [Link to article on publisher's website](#)

Management of type II superior labrum anterior posterior lesions: a review of the literature

Xinning Li,¹ Timothy J. Lin,² Marcus Jager,³ Mark D. Price,¹ Nicola A. Deangelis,¹ Brian D. Busconi,¹ Michael A. Brown¹

¹Department of Orthopaedic Surgery, Division of Sports Medicine, University of Massachusetts Medical Center, Worcester, MA, USA;

²University of Massachusetts Medical School, Worcester, MA, USA;

³Heinrich-Heine-University Medical School, Dusseldorf, Germany

Abstract

Superior labrum anterior and posterior lesions were first described in 1985 by Andrews *et al.* and later classified into four types by Snyder *et al.* The most prevalent is type II which is fraying of the superior glenoid labrum with detachment of the biceps anchor. Superior labrum anterior posterior (SLAP) lesions can also be associated with other shoulder pathology. Both MRI and MRA can be utilized in making the diagnosis with the coronal images being the most sensitive. The mechanism of injury can be either repetitive stress or acute trauma with the superior labrum most vulnerable to injury during the late cocking phase of throwing. A combination of the modified dynamic labral shear and O'Brien test can be used clinically in making the diagnosis of SLAP lesion. However, the most sensitive and specific test used to diagnosis specifically a type II SLAP lesion is the Biceps Load Test II. The management of type II SLAP lesions is controversial and dependent on patient characteristics. In the young high demanding overhead athlete, repair of the type II lesion is recommended to prevent glenohumeral instability. In middle-aged patients (age 25-45), repair of the type II SLAP lesion with concomitant treatment of other shoulder pathology resulted in better functional outcomes and patient satisfaction. Furthermore, patients who had a distinct traumatic event resulting in the type II SLAP tear did better functionally than patients who did not have the traumatic event when the lesion was repaired. In the older patient population (age over 45 years), minimum intervention (debridement, biceps tenodesis/tenotomy) to the type II SLAP lesion results in excellent patient satisfaction and outcomes.

Introduction

Superior glenoid labrum tears as a source of shoulder pain were first described by Andrews *et al.* in 1985 in the context of the high demand throwing athlete (professional baseball pitchers). The pathology correlated with the immense stress placed on the shoulder and the biceps brachialis muscle during the throwing motion.¹ In 1990, Snyder coined the term Superior Labrum Anterior and Posterior (SLAP) tear to describe the pathology of the labrum in overhead throwing athletes as previously proposed by Andrews *et al.* Four unique types of superior labrum pathology were classified after inspection via arthroscopy (Illustration 1).² While the lesions that Andrews and Snyder described were associated with athletic injuries, it has been demonstrated that SLAP lesions are often found in association with other shoulder pathology especially rotator cuff tears in older patients with chronic shoulder overuse. Type II SLAP tears were the most common type of tear found by Snyder based on his original manuscript. While there have been some improvements on the diagnosis, classification, and repair of type II SLAP tears, their management is controversial and continues to evolve.

Types of superior labrum anterior posterior lesions

In the first classification of SLAP lesions, Snyder *et al.* described four distinct types of superior labrum pathology.² Type I lesions were described by Snyder *et al.* as being more common in an older population of patients, middle-aged to elderly, and marked by fraying and signs of degeneration of the superior labrum from the nine o'clock to the three o'clock position.³ These lesions are the least prevalent type, seen in only 11% of the patients (3/27). In addition, to be classified as a type I SLAP lesion, the long head of the biceps tendon must be fully intact at the glenoid attachment site. Type II lesions were described as the most prevalent of the SLAP lesions and were present in 41% of the patients (11/27). In addition to the fraying of the superior glenoid labrum seen in the type I SLAP lesions, type II lesions have an associated detachment of the biceps tendon from superior glenoid tubercle.² Type III lesions were found to be the second most prevalent among the patients, at 33% of the total number of patients (9/27). These lesions are often described using the term "bucket-handle" tear, as the superior labrum is completely detached from the superior glenoid rim, with the biceps tendon intact. Type IV lesions were described as a combination of type II and type III tears. A bucket-handle tear is seen as in the labrum with extension of the tear into the biceps tendon and inferior displacement of

Correspondence: Xinning Li, Department of Orthopaedic Surgery, Division of Sports Medicine, University of Massachusetts Medical Center, Worcester, MA, USA
E-mail: xinning.li@gmail.com

Key words: SLAP, type II lesion, arthroscopy, sports medicine, literature review.

Received for publication: 7 October 2009.

Revision received: 12 December 2009.

Accepted for publication: 15 December 2009.

This work is licensed under a Creative Commons Attribution 3.0 License (by-nc 3.0).

©Copyright Xinning Li *et al.*, 2010
Licensee PAGEPress, Italy
Orthopedic Reviews 2010; 2:e6
doi:10.4081/or.2010.e6

the tear into the shoulder joint. The prevalence of type IV lesions was found in 15% of the study patients (4/27). Illustration 1 depicts the four types of SLAP lesions (Snyder classification). Since Snyder's original article, several authors have added more extensive classifications of SLAP tears including types V-VII,⁴ types VIII and IX,⁵ and type X.⁶ Type II SLAP Lesions have also been separated into type II a, b, and c.⁷ These additional classification and subtypes of the SLAP lesions are not commonly used when compared to the original classification by Snyder *et al.*

Although it is difficult to estimate the epidemiology of each type of SLAP lesion in the population, a recent study published in the *Journal of Bone and Joint Surgery* reported the prevalence of SLAP lesions to be 26% (139 patients) in 544 consecutive patients undergoing shoulder arthroscopy. Out of these patients, 74% (103/139) had type I lesions, 21% (29/139) had type II lesions, 0.7% (1/139) had type III lesions, and 4% (6/139) were found to have type IV lesions. Furthermore, Bankart lesions were associated in patients who were under the age of 40 years with type II SLAP tears and a supraspinatus tear with osteoarthritis of the humeral head is associated with patients who were over the age of 40 who had a type II SLAP tear.⁸

Anatomy and diagnosis of superior labrum anterior and posterior tears on MRI/MRA

The glenoid labrum is a rim of fibrocartilaginous tissue that lines the edges of the glenoid cavity and which deepens the glenoid cavity to provide extra static stability to the shoulder joint. The superior glenoid labrum also serves as the site of attachment of the glenohumeral ligaments and the tendon of the long head of the biceps brachii muscle. The

system most commonly used to identify regions of the glenoid labrum when describing lesions is to compare the circular or pear shaped glenoid to the face of a clock, with 12 o'clock corresponding to superior labrum, 3 o'clock to anterior, 6 o'clock to inferior, and 9 o'clock to the posterior position.

There are several common normal variants of shoulder anatomy that can lead to confusion when evaluating a shoulder MRI for SLAP lesions.⁹ First, the glenoid labrum is most mobile at the superior pole and the attachment site can be relatively loose. Therefore this normal loose anatomy can sometimes be confused with a type II SLAP tear.⁵ Additionally, the presence of a sublabral recess (sulcus), sublabral foramen (hole or space between the anterosuperior labrum and the glenoid cartilage), or Buford complex (cord-like middle glenohumeral ligament) which are all normal variants can lead to a false diagnosis of SLAP lesions.⁹ The sublabral recess which was first described by De Palma *et al.*¹⁰ can be especially difficult to distinguish from a type II SLAP lesion. This normal anatomic variant has an increasing prevalence associated with age and was seen in 95% of the cadavers aged 60-79. While sublabral recess is not considered pathological, it has been hypothesized that it can lead to a higher rate of SLAP lesions if stressed with overhead activities.¹¹

SLAP tears are routinely diagnosed using Magnetic Resonance Imaging (MRI). Given the complexity of the shoulder anatomy, the normal variations seen across the population, associated injury patterns, and poor inter-observer reliability in the classification of SLAP tears, the use of an algorithm has been suggested in order to systematically define SLAP lesions of the shoulder.⁹ MRI signs of a SLAP lesion include increased signal of the glenoid labrum with or without extension into the biceps tendon and cleavage of the superior glenoid labrum.¹² Both the coronal (Figure 1) or the axial (Figure 2) MRI images can be used to make the diagnosis of a type II SLAP tear.

While Magnetic Resonance Arthrogram (MRA) of the shoulder is not considered a routine test for diagnosis of SLAP lesions,¹³ it can be considered in patients with MRI who show inconclusive findings or findings that are questionable for normal anatomical variations.⁵

The algorithm proposed by Mohana-Borges *et al.* for the systematic evaluation of MRI to diagnose SLAP lesions involves first evaluating the biceps-labral complex. Labral tears are further characterized as either non-displaced or displaced. The second step is determining the extension of this tear into other areas of the labrum. The last step is to evaluate for associated abnormalities of the glenohumeral

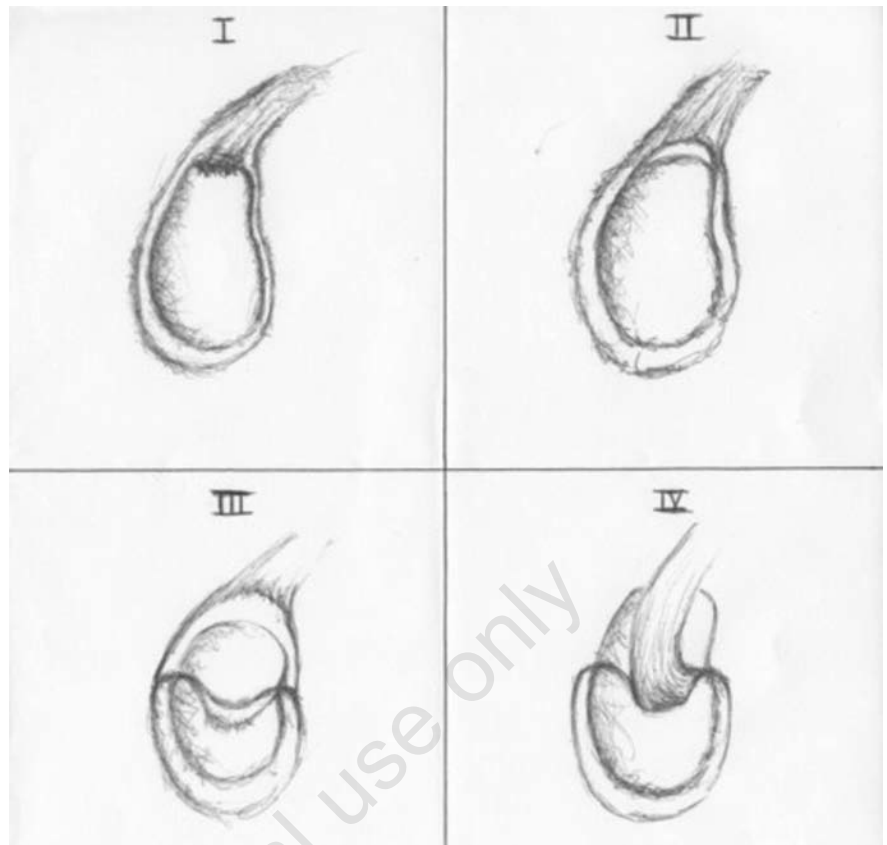


Illustration 1. The four types of SLAP lesions (Snyder classification).

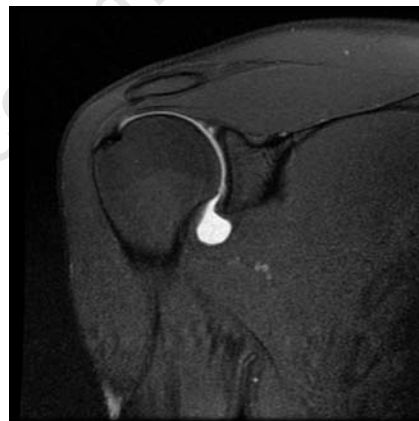

Figure 1. Coronal MRI image of the shoulder showing extravasation of the contrast media into the type II SLAP tear.

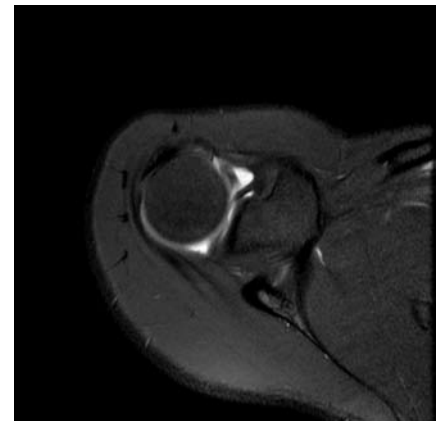

Figure 2. Axial MRI demonstrating tear of the superior labrum from the anterior to the posterior direction consistent with a type II tear.

ligament, joint capsule, articular cartilage, and tendons.⁹ The sensitivity and specificity of MRI for the diagnosis of SLAP lesions have been reported as 98% and 89.5%, respectively.¹⁴ While the sensitivity and specificity of MRA for the diagnosis of SLAP lesions are reported to be 89% and 91%, respectively.¹⁵

Biomechanical studies

Many theories have been proposed to explain the mechanisms involved in developing a type II SLAP tear. However, they can all be divided into two main categories: those caused by repetitive motion and those caused by acute

trauma. When Andrews *et al.* first described this superior labral pathology, they implicated the repetitive eccentric action and extreme force of the long head of the biceps tendon placed on the superior aspect of the labrum during the arm deceleration and follow-through phases of throwing.¹ Burkhart and Morgan described what is known as the “peel-back” mechanism as a possible cause of SLAP tears. They hypothesize that the combination of arm abduction and external rotation during the late cocking phase of throwing places a torsional strain on the insertion of the long head of the biceps tendon on the labrum, thus resulting in SLAP lesions.¹⁶ Proposed mechanisms of acute trauma leading to a type II SLAP tear include falling onto an outstretched arm. It is hypothesized that the humeral head is pushed back upon the superior labrum resulting in a tear in the biceps-labrum complex.

The differences in the ultimate strength of the biceps anchor and the generation of a type II SLAP lesion was evaluated in a cadaver study. The ultimate force load at failure with biceps loading (representing deceleration and follow-through motions) was compared with posterior vector loading (representing the late cocking phase of throwing). The biceps tendon showed significantly more ultimate strength with axial or in-line loading when compared with posterior vector loading. Furthermore, none of the specimens in the axial loaded group resulted in a type II SLAP lesion while all of the specimens in the posterior vector loaded group resulted in a type II SLAP lesion at failure. This study concluded that the superior labrum may be the most vulnerable to injury in the late cocking phase of throwing.¹⁷

Glenohumeral instability has also been associated with SLAP lesions, though the reason for this association has not been proven and instability has not been correlated with type II SLAP lesions in particular. Whether glenohumeral instability arises due to the presence of a SLAP lesion or the SLAP lesion comes about due to the increased laxity or chronic instability, remains to be determined.

Clinical exam maneuvers

Attempts have been made to correlate physical exam maneuvers to the proposed causative mechanisms of SLAP lesions in order to selectively identify SLAP lesions by reproducing pain with the maneuvers. Recently, Kibler *et al.* evaluated the accuracy of current clinical tests for the diagnosis of biceps tendon injuries and SLAP lesions.¹⁸ In a prospective analysis of patients presenting with shoulder pain, they compared clinical exam maneuvers with intraoperative findings and evaluated the sensitivity, specificity, accuracy, positive predictive value (PPV), and negative predictive value (NPV) for each maneuver/test. Statistical analysis was also performed to determine the

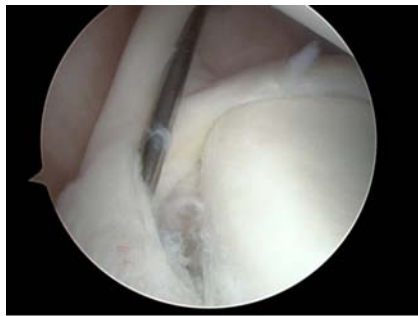

Figure 3. Arthroscopic picture showing the type II superior labrum tear from an anterior (3 o'clock) to posterior (9 o'clock) direction. An 18 gauge needle is used to elevate the tear.

best test or combination of tests for the diagnosis of SLAP lesions. They found that the modified Dynamic Labral Shear (mDLS) test had a sensitivity of 72% and a specificity of 98% for diagnosing SLAP lesions. However, further accuracy can be achieved using a combination of the modified DLS (mDLS) and O'Brien's maneuvers.¹⁸ The mDLS is performed with the patient standing, the elbow flexed to 90°, the shoulder abducted to above 120° and maximally externally rotated. Then the arm is worked gently into maximal horizontal abduction with the examiner holding a shear load to the joint by holding the external rotation and horizontal abduction. Subsequently, the arm is slowly lowered from 120° to 60° of abduction, with a positive test indicated by pain or the presence of a painful click or catch along the posterior joint line. This test was meant to stimulate the peel back mechanism.¹⁸

A more sensitive and specific test for type II SLAP lesions has recently been proposed by Kim *et al.*, termed the Biceps Load Test II.¹⁹ It is performed with the patient in the supine position and the arm is elevated to 120° and externally rotated to its maximal position. The elbow is flexed to 90° and the forearm is supinated. The patient is then asked to flex the elbow with resisted force by the examiner. This test is considered positive if the patient complains of pain with the resisted elbow flexion. The test is negative if pain is not elicited or if the pre-existing pain with the arm elevation and external rotation is unchanged or diminished. A double blinded prospective study was performed on 127 patients to evaluate the sensitivity and specificity with confirmation via arthroscopy and found the value to be 89.7% and 96.9%, respectively, for making the diagnosis of type II SLAP lesions.¹⁹

Arthroscopic portals utilized in the treatment of superior labrum anterior and posterior lesions

There have been several portals described

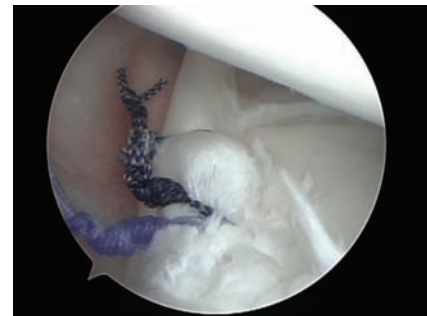

Figure 4. Repair of the type II SLAP tear with suture anchors.

for repair of SLAP lesions. Such lesions can be repaired viewing through a posterior portal and working through a standard anterosuperior portal²⁰ a mid-glenoid portal,²¹ or anteroinferior portal.²² Similarly, O'Brien described the creation of a trans-rotator cuff portal for repair when the lesion is posterior to the biceps tendon,²³ and Burkhart has advocated use of a posterolateral portal (Port of Wilmington) as part of a SLAP repair.²⁴ More recently, Nord *et al.* described the use of the Neviasser portal, a superior medial portal, as the working portal in SLAP repairs.²⁵ No one portal has been found to be optimal for all types of repairs, and often surgeon preference combined with the location of the lesion helps dictate the working portal in SLAP repair.

Management of type II superior labrum anterior and posterior lesions

Repair of the type II SLAP lesions (Figure 3) has been repeatedly shown to be a successful procedure in the young overhead athlete. The percentage of these patients achieving good or excellent results as measured with patient satisfaction and functional outcome with type II SLAP repair using suture anchors (Figure 4) has ranged from 87-94%^{7,26,27} with repair using a bioabsorbable tack from 70-88%.^{28,30} Recent studies have provided some insight into predicting outcome of type II SLAP repair based on patients' characteristics and technique. The outcome of treatment of type II SLAP repairs depends on several factors. These include associated shoulder pathology, mechanism of injury, patient expectations, and the most notable factor which is the age of the patient. In the past, the consensus has been to repair isolated type II SLAP lesions using a single-anchor, double-suture technique in part to preserve glenohumeral stability.³ Recent clinical studies have started to show that a certain population of patients may, in fact, do better with biceps tenodesis, tenotomy, or debride-

Table 1. A summary of the recent literature on type II SLAP lesions.

Author	Journal	Type of study	Demographics	Follow-up	Comparison time	Outcome measures	Conclusions
Abbot <i>et al.</i> (2009) ¹³	Am J Sports Med	Cohort	Pts > 45 years With RTC tear and Type II SLAP lesion n=48 mean age 51.9	2 years	RTC repair with type II SLAP debridement vs. RTC repair and type II SLAP repair	Tegner score UCLA score Clinical ROM	Better function, pain relief, and ROM in patients undergoing debridement of type II SLAP lesions when compared with repair of type II SLAP lesion
Boileau <i>et al.</i> (2009) ³¹	Am J Sports Med	Cohort	Ages 19-64 Isolated type II SLAP lesion. n=25 Mean age in SLAP repair group: 37 Mean age in Biceps tenodesis group: 52	Avg of 35 months post-op	Pain and return to previous level of sports participation after either SLAP repair with suture anchor or Biceps tenodesis with absorbable interference screw	Subjective satisfaction scale Pain (VAS)** Constant score for functional outcome	Biceps tenodesis is an acceptable alternative to labrum reinsertion using suture anchors for repair of unstable isolated type II SLAP lesions, even for overhead athletes. Return to previous level of sports participation much better with Biceps tenodesis (93% satisfied) than with SLAP repair (40% satisfied)
Brockmeier SF <i>et al.</i> (2009) ²⁶	JBJs	Prospective	39 men, 8 women with type II SLAP tears n=47	Avg of 2.7 years	Arthroscopic repair using suture anchor fixation of type II SLAP lesions in patients with traumatic etiology vs. patients with no distinct trauma	ASES* and L'Insalata scores	No significant difference in ASES or L'Insalata scores between patients with a traumatic etiology vs. patients without traumatic etiology. Median patient-reported satisfaction higher in patients with traumatic etiology (9 vs. 7 out of 10, respectively)
Coleman <i>et al.</i> (2007) ²⁸	Am J Sports Med	Case series	Patients with type II SLAP lesion +/- dx of subacromial decompression n=50 SLAP group avg age: 34 (16-56) Combined group avg age: 42 (33-71)	Avg of 3.4 years, min of 2 years	Comparison of outcome between SLAP repair only (SLAP group) and SLAP repair and acromioplasty (Combined group)	ASES and L'Insalata scores, subjective evaluation	Similar ASES and L'Insalata scores in both SLAP only group and Combined group (86.5 vs. 85.8 and 87.1 vs. 85.1, respectively) 65% of the SLAP only group reported a "Good-excellent" result vs. 81% in the combined group (P<0.05). No reports of post-op loss of motion in the Combined group.
Enad <i>et al.</i> (2007) ²⁷	Knee Surg Sports Traumatol Arthrosc n=36	Retrospective Review	Age 22-41 (avg 31.6) Active duty member of military service at time of tx Grp I: n=18 – isolated type II SLAP tear Grp II: n=18 – type II SLAP tear	Avg 29.1 months	Isolated repair of type II SLAP tears vs. repair of type II SLAP tear and repair of other associated shoulder pathology (Subacromial impingement, AC arthrosis, spinoglenoid cyst, intra-articular loose bodies)	UCLA score ASES score VAS pain score	Better results in 2/3 parameters in group II vs group I. 17 of 18 in both groups returned to active duty. Conclusion. Treatment of associated extra-articular shoulder conditions improves outcome s/p SLAP type II repair.

Continue on next page

Table 1 [continued]. A summary of the recent literature on type II SLAP lesions.

Author	Journal	Type	Demographics	Follow-up	Comparison	Outcome	Conclusions
Franceschi <i>et al.</i> (2008) ³²	Am J Sports Med	RCT	Pts > 50 years Men and Women with type II SLAP lesion and RTC tear n=63	Minimum 2.9 years	RTC repair and Biceps Tenotomy vs. RTC repair and type II SLAP repair	UCLA score Clinical Range of motion (ROM)	RTC repair and Biceps tenotomy leads to better clinical outcome based on UCLA score and ROM when compared with repair of both the RTC tear and type II SLAP lesion in patients over 50
O'Brien <i>et al.</i> (2002) ²³	Arthroscopy	Retrospective clinical follow-up study	Arthroscopic type II SLAP repair using trans-rotator cuff portal n=31	Avg 3.7 years, min 2 years		L'Insalata and ASES	Avg L'insalata 87, ASES 87.2, Average pain score 1.5 (0-5), 16/31 returned to pre-injury level of sports, 11 returned to limited activity. 22/31 reported good/ excellent overall satisfaction. None had symptoms suggesting resultant RTC pathology. Trans RTC approach allows better placement of fixation for SLAP repairs.

*ASES: American Shoulder and Elbow Surgeons. **VAS: Visual Analog Scale. UCLA score : assesses pain, function, active forward elevation, strength of forward motion, and patient satisfaction. Tegner score is a self-reported activity level score, originally used in evaluating knee injuries

ment of the type II SLAP lesion as an alternative to repair with suture anchors or absorbable tacks.^{13,23,26-28,31,32}

It has been proposed that the use of a trans-rotator cuff portal may lead to consequent rotator cuff (RTC) pathology. O'Brien *et al.* published a retrospective clinical follow-up study in 2002, which demonstrated that, in contrast to the conclusions of previous studies, of the 31 patients undergoing type II SLAP repair using a trans-rotator cuff portal, 71% had good to excellent results at an average follow-up of 3.7 years.²³ None had symptoms suggestive of resultant RTC pathology. This paper also argued that the trans-rotator cuff approach allowed for better placement of fixation for SLAP repairs.

Two recent studies have investigated the outcome of isolated type II SLAP repair versus SLAP repair along with treatment of associated shoulder pathology. A case series of 50 patients by Coleman *et al.* investigated whether repair of type II SLAP lesions with simultaneous acromioplasty for impingement syndrome worsened outcome when compared to isolated SLAP repair, the underlying fear of some orthopedic surgeons being that subacromial decompression and acromioplasty might lead to decreased range of motion caused by increased inflammation secondary to surgery which may worsen the outcome of the SLAP repair. This study showed that 65% of the patients in the SLAP repair only group had a

good or excellent result while 81% of patients in the SLAP repair plus acromioplasty group had a good or excellent result ($P<0.05$).²⁸ Notably the patients in the SLAP only group were on average eight years younger (34 vs. 42 years) and more were athletes than in the SLAP plus acromioplasty group. It's possible that younger and more athletic patients have increased reliance on their shoulders and thus are more dissatisfied when their use of their shoulders is decreased as compared to older and less athletic patients.²⁸ Enad *et al.* published a retrospective review of 36 active duty military servicemen comparing isolated repair of type II SLAP lesions with repair of the SLAP lesion combined with addressing the associated ipsilateral shoulder pathology (subacromial impingement, AC arthrosis, spinoglenoid cyst, and intraarticular loose bodies). Using University of California Los Angeles (UCLA), American Shoulder and Elbow Scores (ASES), and Visual Analog Score (VAS), the study concluded that repair of the SLAP lesion combined with the associated shoulder pathology leads to better results in the UCLA and ASES scores when compared to repair of SLAP lesion alone.²⁷ Together these studies suggest that if patients are found intra-operatively to have associated shoulder pathology along with a type II SLAP lesion, they will likely do better with repair of both the SLAP lesion and the associated pathology.

It has been hypothesized that patients who

have had a type II SLAP lesion as the result of a specific and distinct trauma may potentially have a more successful outcome after repair when compared to patients in whom a distinct traumatic event cannot be identified. Brockmeier *et al.* published a recent prospective study comparing arthroscopic repair of type II SLAP lesions in patients with traumatic etiology with patients who had type II SLAP lesions without a distinct traumatic etiology. They found that although the two groups had statistically similar ACES and L'insalata scores, the patients in the traumatic etiology group had significantly higher median patient-reported satisfaction when compared with those patients without a traumatic etiology (9/10 vs. 7/10; $P<0.05$).²⁶ Furthermore, more athletes who had a distinct traumatic etiology were able to return to their previous sports after arthroscopic type II SLAP repair than athletes who did not have a distinct traumatic event (92% vs. 74%). This study group had an average age of 36 years (range 14-49).²⁶

The utility of repairing type II SLAP tears in the older patient population has been recently questioned. Abbot *et al.* described a cohort of 48 patients over the age of 45 years with type II SLAP lesions and associated rotator cuff tears (RCT's) who all underwent repair of the RTC tear. In one group there was concomitant SLAP debridement while the other underwent SLAP repair. The patients in the debridement group were found at the 2-year follow-up to have sig-

nificantly better UCLA shoulder function, pain relief, and range of motion compared with those in whom SLAP lesions were repaired.¹³ Another recent randomized controlled trial evaluated 63 patients over the age of 50 years who underwent both a RTC repair and type II SLAP repair or who had RTC repair and debridement of the SLAP lesion with biceps tenotomy. The group who had a SLAP debridement and tenotomy showed significantly better UCLA scores and range of motion at the mean of 2.9 years follow-up. More specifically, patients in the debridement and tenotomy group had final UCLA scores of 32.1 versus 27.9, forward flexion of 166° versus 139°, and better overall patient satisfaction.³²

The utility of repair of a type II SLAP tear was further put into question by a recent study by Boileau *et al.* In this cohort of 25 patients aged 19-64 years with isolated type II SLAP lesions, biceps tenodesis with an absorbable interference screw was compared with SLAP repair using suture anchors. Pain, function (Constant Scores), return to previous sporting activity, and patient satisfaction were used as outcome measures. They found that the patients undergoing biceps tenodesis reported significantly better satisfaction and better return to previous levels of activity when compared to those patients undergoing SLAP repair. Furthermore, 4 patients who failed SLAP repair subsequently underwent biceps tenodesis and were able to return to their previous level of sporting activity. It's important to consider that the average age of the patients in the two groups differed significantly: the average age of the patients undergoing SLAP repair was 37 years while the patients undergoing tenodesis was 52 years.³¹ It was proposed that the tenodesis group could be a lower demand population and thus resulted in the better overall outcomes. The above data are consistent with the conclusions of Abbott *et al.*¹³ and Franceschi *et al.*³² that while younger overhead athletes may warrant repair of the type II SLAP lesions, older patients may do better with minimum intervention to the type II SLAP lesions.

Conclusions

The management of the type II SLAP lesions is controversial and dependent on patients' characteristics (see Table 1 for summary). In the young high demand overhead athlete, repair of the type II lesion is recommended to prevent glenohumeral instability. In the middle-aged patients (age 25-45 years), repair of the type II SLAP lesion with concomitant treatment of other shoulder pathology resulted in better functional outcomes and patient satisfaction. Furthermore, patients who had a distinct traumatic event resulting in the type II

SLAP tear did better functionally than patients who did not have the traumatic event when the lesion was repaired. In the older patient population (age over 45 years), minimum intervention (debridement, biceps tenodesis/tenotomy) to the type II SLAP lesion resulted in excellent patient satisfaction and outcomes.

References

- Andrews JR, Carson WG, McLeod WD. Glenoid labrum tears related to the long head of the biceps. *Am J Sports Med* 1985;13:337-41.
- Snyder SJ, Karzel RP, Del Pizzo W, et al. SLAP lesions of the shoulder. *Am J Sports Med* 1990;6:274-9.
- Nam EK, Snyder SJ. Clinical sports medicine update. The diagnosis and treatment of superior labrum, anterior and posterior (SLAP) lesions. *Am J Sports Med* 2003;31:798-810.
- Maffet MW, Gartsman GM, Moseley B. Superior labrum-biceps tendon complex lesions of the shoulder. *Am J Sports Med* 1995;23:93-8.
- Resnick D, Kang H. Internal derangements of joints: Emphasis on MR imaging. Edited by Resnick, D. pp. 171-281, Philadelphia, Saunders, 1997.
- Beltran J, Bencardino J, Mellado JM, et al. MR arthrography of the shoulder: normal variants and pitfalls. *Radiographics* 1997;17:1403-12.
- Morgan CD, Burkhart SS, Palmeri M, et al. Type II SLAP lesions: three subtypes and their relationships to superior instability and rotator cuff tears. *Arthroscopy* 1998;14:553-65.
- Kim TK, Queale WS, Cosgarea AJ, et al. Clinical features of the different types of SLAP lesions. *J Bone Joint Surg Am* 2003;85:66-71.
- Mohana-Borges AVR, Chung CB, Resnick D. Superior labral anteroposterior tear: classification and diagnosis on MRI and MR arthrography. *AJR Am J Roentgenol* 2003;181:1449-62.
- DePalma AF, Gallery G, Bennett GA. Variational anatomy and degenerative lesions of the shoulder joint. Instructional Course Lectures 6. *J Am Acad Orthop Surg* 1949;225-81.
- Fealy S, Rodeo SA, Dicarlo EF, et al. The developmental anatomy of the neonatal glenohumeral joint. *J Shoulder Elbow Surg* 2000;9:217-22.
- Monu JU, Pope TL, Chabon SJ, et al. MR diagnosis of the superior labral anterior posterior (SLAP) injuries of the glenoid labrum: value of routine imaging without intraarticular injection of contrast materi-
- al. *Am J Radiol* 1994;163:1425-29.
- Abbot AE, Li X, Busconi BD. Arthroscopic Treatment of concomitant superior labral anterior posterior (SLAP) lesions and rotator cuff tears in patients over the age of 45 years. *Am J Sports Med* 2009;37:1358-62.
- Connell D, Potter H, Wickiewicz T, et al. Noncontrast magnetic resonance imaging of superior labral lesions. *Am J Sports Med* 1999;27:208-13.
- Bencardino J, Beltran J, Rosenberg Z, et al. Superior labrum anterior-posterior lesions: diagnosis with MR arthrography of the shoulder. *Radiology* 2000;214:267-71.
- Burkhart SS, Morgan CD. The peel-back mechanism: its role in producing and extending posterior type II SLAP lesions and its effect on SLAP repair rehabilitation. *Arthroscopy* 1998;14:637-40.
- Shepard MF, Dugas JR, Zeng N, et al. Differences in the ultimate strength of the biceps anchor and the generation of type II superior labral anterior posterior lesions in a cadaveric model. *Am J Sports Med* 2004;32:1997-201.
- Kibler WB, Sciascia AD, Hester P, et al. Clinical utility of traditional and new tests in the diagnosis of biceps tendon injuries and superior labrum anterior and posterior lesions in the shoulder. *Am J Sports Med* 2009;37:1840-7.
- Kim SH, Ha KI, Ahn JH, et al. Biceps Load Test II: A clinical test for SLAP lesions of the shoulder. *Arthroscopy* 2001;17:160-4.
- Burkhart S, Morgan C, Kibler W. The disabled throwing shoulder: spectrum of pathology part II: evaluation and treatment of SLAP lesions in throwers. *Arthroscopy* 2003;19:531-9.
- Mileski R, Snyder S. Superior labral lesions in the shoulder (Pathoanatomy and surgical management). *J Am Acad Orthop Surg* 1998;6:121-31.
- Rames R, Karzel R. Injuries to the glenoid labrum, including SLAP lesions. *Orthop Clin North Am* 1993;24:45-53.
- O'Brien SJ, Allen AA, Coleman SH, et al. The trans-rotator cuff approach to SLAP lesions: technical aspects for repair and a clinical follow-up of 31 patients at a minimum of 2 years. *Arthroscopy* 2002;18:372-7.
- Burkhart S, Morgan C. SLAP lesions in the overhead athlete. *Orthop Clin North Am* 2001;32:431-41.
- Nord K, Masterson J, Mauck B. Superior labrum anterior posterior (SLAP) repair using the Neviaser portal. *Arthroscopy* 2004;20:129-33.
- Brockmeier SF, Voos JE, Williams RJ, et al. Outcomes after arthroscopic repair of type II SLAP lesions. *J Bone Joint Surg Am*

- 2009;91:1595-63.
27. Enad JG, Gaines RJ, White SM, et al. Arthroscopic superior labrum anterior-posterior repair in military patients. *J Shoulder Elbow Surg* 2007;16:300-5.
28. Coleman SH, Cohen DB, Drakos MC, et al. Arthroscopic repair of type II superior labral anterior posterior lesions with and without acromioplasty. *Am J Sports Med* 2007;35:749-53.
29. Cohen DB, Coleman S, Drakos MC, et al. Outcomes of isolated type II SLAP lesions treated with arthroscopic fixation using a bioabsorbable tack. *Arthroscopy* 2006;22:136-42.
30. Samani JE, Marston SB, Buss DD. Arthroscopic stabilization of type II SLAP lesions using an absorbable tack. *Arthroscopy* 2001;17:19-24.
31. Boileau P, Parratte S, Chuinard C, et al. Arthroscopic treatment of Isolated Type II SLAP lesions. *Am J Sports Med* 2009;37:929-36.
32. Franceschi F, Longo UG, Ruzzini L, et al. No advantages in repairing a type II superior labrum anterior and posterior (SLAP) lesion when associated with rotator cuff repair in patients over age 50. *Am J Sports Med* 2008;36:247-53.

Non-commercial use only