

## NEUROLOGICAL BULLETIN

FEATURING ARTICLES BY TRAINEES IN NEUROLOGY &amp; NEUROSCIENCE

**L5 Radiculopathy Causing Ipsilateral Absent Superficial Peroneal Sensory Response**

David Cachia and Johnny Salameh

Department of Neurology  
University of Massachusetts Medical School, Worcester, MA

A dogma in neurophysiologic studies states that an absent/reduced sensory nerve action potential (SNAP) implies a lesion at the level/distal to the dorsal root ganglion (DRG). Radiculopathies being proximal to the DRG generally have normal SNAPs. A 28-year-old patient presented with right lower extremity radicular symptoms. Nerve conduction studies (NCS) revealed an absent right superficial peroneal sensory response. MRI of the lumbosacral spine showed a right L4-5 disc extrusion compressing the L5 nerve root. An isolated absent superficial peroneal SNAP may rarely occur if the DRG is located within the intraspinal canal or proximal to the intervertebral foramen and does not exclude an L5 radiculopathy.

**Case Report**

A 28-year-old gentleman presented with a 4 month history of tingling sensation in his right calf muscle that over weeks progressed to pain radiating from the lower back to the right calf. He also described numbness over the lateral border of his right foot up to the ankle area.

Manual muscle testing revealed a medical-

research-council grade of 4/5 of the right extensor hallucis longus, with the rest of the neurologic examination being normal. NCS showed an absent right superficial peroneal SNAP, moderately reduced amplitude of the right peroneal compound muscle action potential, and mildly prolonged latency with reduced amplitude of the right tibial H reflex. Both sural SNAPs were normal. Needle electromyography (EMG) showed increased insertional activity and abnormal spontaneous activity in the form of fibrillation potentials and positive sharp waves in the right tensor fascia lata, tibialis posterior, peroneus longus as well as the right lumbosacral paraspinals. Increased insertional activity was also noted in the right tibialis anterior and the right medial gastrocnemius. An increased percentage of high amplitude, long duration polyphasic units with mildly reduced recruitment was noted in the right tensor fascia lata, tibialis posterior, peroneus longus, tibialis anterior and medial gastrocnemius. In summary, the NCS/EMG was suggestive of active right-sided L5-S1 radiculopathy.

Magnetic-resonance-imaging (MRI) of the lumbosacral spine showed a right paracentral

---

Correspondence to David Cachia: davidcachia@gmail.com

Keywords: radiculopathy, dorsal root ganglion, superficial peroneal sensory response, herniated disc

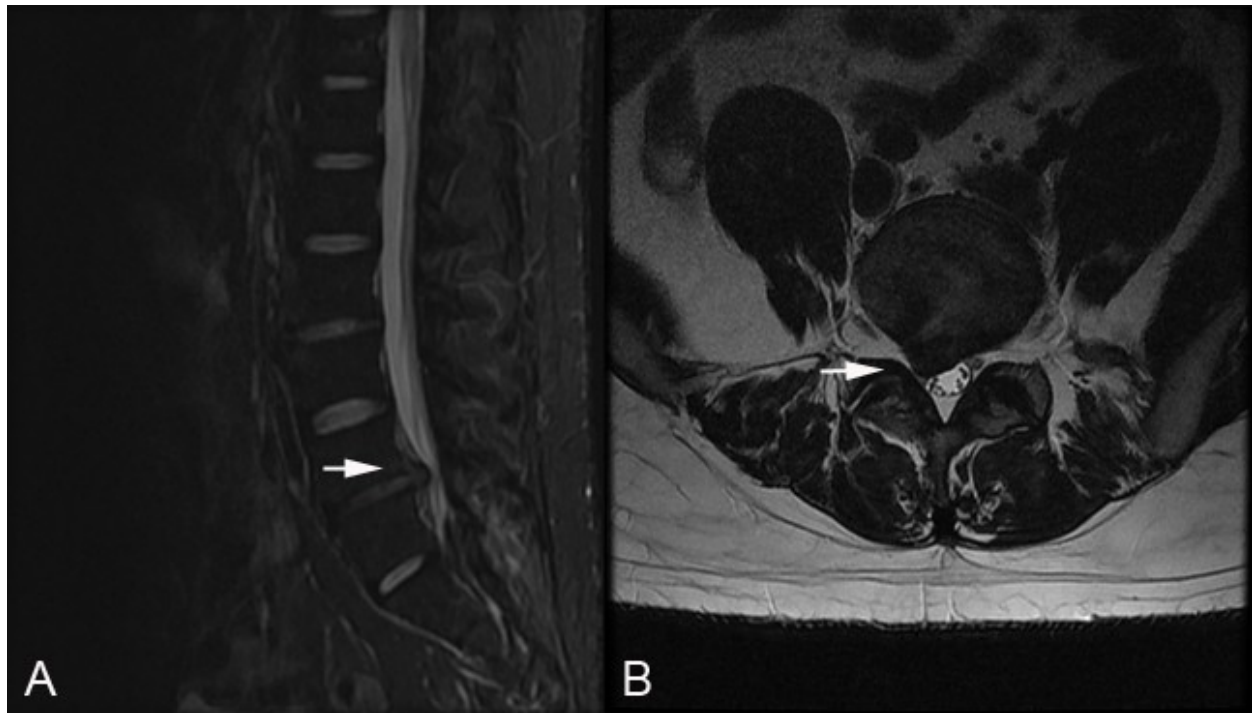


Figure 1: Lumbosacral MRI. **a.** L4-5 disc prolapse on sagittal MRI (arrow) **b.** L4-5 right paracentral disc extrusion compressing right L5 nerve root as it exits the thecal sac (arrow).

disc extrusion on the right effacing the lateral recess and compressing the right L5 root as it exits the thecal sac (Figure 1).

## Discussion

A rule in electrodiagnostic studies states that an absent or reduced SNAP implies a lesion at the level or distal to the DRG. Radiculopathies, being proximal to the DRG generally have normal SNAPs. This case is an exception to this rule showing evidence of an L5 radiculopathy causing involvement of the DRG or sensory complex. The needle findings seen in the medial gastrocnemius could be explained by the fact that this muscle receives some innervation from the L5 root, though the majority of its innervation derives from S1-S2 nerve roots. It is postulated that an absent superficial peroneal SNAP in an L5 radiculopathy occurs if the DRG is located within the intraspinal canal or proximal to

the intervertebral foramen. Though the classical teaching is that the DRG resides within the intervertebral foramen, different studies using various techniques to localize the DRG have confirmed that the L5 DRG may be located in the intraspinal canal.<sup>1</sup> Techniques used to localize the DRG ranged from radiographic studies to post-mortem analysis. This location makes it vulnerable to compression from disc prolapse or joint disease leading to axon loss along peripheral sensory fibers with resulting loss of the distally evoked SNAP. In a prospective study by Mondelli et al.,<sup>2</sup> they demonstrated how lumbosacral radiculopathies from herniated discs result in reduced or absent SNAPs in only 7% of cases. This confirms how rare this occurrence is and that the electrophysiological dogma stating that SNAPs have normal amplitude in radiculopathies stands most of the time, broken only in exceptional cases.

## References

1. Levin KH. L5 radiculopathy with reduced superficial peroneal sensory responses: intraspinal and extraspinal causes. *Muscle Nerve* 1998;21:3-7, [http://dx.doi.org/10.1002/\(SICI\)1097-4598\(199801\)21:1<3::AID-MUS1>3.0.CO;2-G](http://dx.doi.org/10.1002/(SICI)1097-4598(199801)21:1<3::AID-MUS1>3.0.CO;2-G)
2. Mondelli M, Aretini A, Arrigucci U, Ginanneschi F, Greco G, Sicurelli F. Sensory nerve action potential amplitude is rarely reduced in lumbosacral radiculopathy due to herniated disc. *Clin Neurophysiol* 2013;124:405-409, <http://dx.doi.org/10.1016/j.clinph.2012.07.020>

*Disclosure:* the authors report no conflicts of interest.

All content in *Neurological Bulletin*, unless otherwise noted, is licensed under a Creative Commons Attribution-Noncommercial-Share Alike License <http://creativecommons.org/licenses/by-nc-sa/3.0/> (ISSN 1942-4043)