http://escholarship.umassmed.edu/neurol_bull

Neurol. Bull. 3: 18-24, 2011
doi:10.7191/neurol_bull.2011.1029

NEUROLOGICAL BULLETIN

FEATURING ARTICLES BY TRAINEES IN NEUROLOGY & NEUROSCIENCE

Morbidity and Mortality Reports: Delay in Diagnosis of Spinal Epidural Abscess

Brian M. Haas, Yen-Hua Yu, and Jongoh Kim

Department of Diagnostic Radiology,
Yale University School of Medicine, New Haven, CT (BH)
Department of Emergency Medicine,
Albert Einstein Medical Center, Philadelphia, PA (YY)
Department of Internal Medicine,
Baylor College of Medicine, Houston, TX (JK)

Introduction

Spinal epidural abscesses frequently exact devastating and lasting neurological deficits and carry a significant risk of mortality. The closed space of the spinal canal leaves little room for abscesses, which can expand to compress the spinal cord. Prompt diagnosis is essential to prevent lasting neurologic injuries and death. Unfortunately, spinal epidural abscesses often have non-specific presentations resulting in delayed diagnosis. This case illustrates the diagnostic difficulty frequently encountered and the devastation easily wrought by the disease.[1-4]

Case Presentation

A 46 year-old female with a history of liver cirrhosis from hepatitis B and C viruses presented with 2 days of progressive back and abdominal pain. The pain was rated as 10/10, but was poorly localized. She described it as shooting all over her back and abdomen. She denied any weakness, bowel and bladder incontinence, or radiation of the back pain into her legs. She had no recent illnesses and denied any fevers or chills. Her past medical history was only remarkable for cirrhosis from hepatitis B and C. The patient admitted to ongoing cocaine and intravenous heroin use.

On examination, the patient was anxious and tearful. She was unable to sit comfortably. She was minimally cooperative with the history and examination. The patient's vital signs were as follows: oral temperature 36.5, heart rate 99, blood pressure 115/66, respiratory rate 16, and pulse ox 99% on room air. Examination of her abdomen was notable for mild tenderness on deep palpation. The reported abdominal pain was thought to be out of proportion to the mild tenderness elicited by exam. The location of the patient's back pain changed from one observer to the next, but there was no appreciable midline spinal tenderness, nor worsening pain with straight leg raise. The assessment of the patient's

Correspondence to Brian Haas: bmhaas@gmail.com
Keywords: Delay in diagnosis of spinal epidural abscess

Neurol. Bull. 3: 18-24, 2011
doi:10.7191/neurol_bull.2011.1029

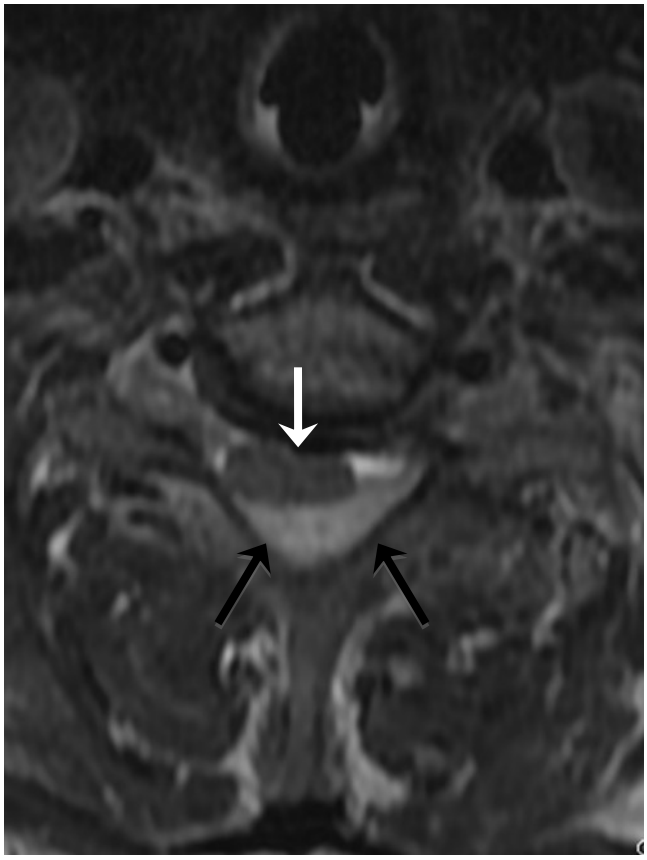

Figure 1: Axial T2 weighted image at the level of the C6-C7 intervertebral disc space demonstrates the abscess (black arrows) displacing the spinal cord (while arrow) anteriorly and towards the right.

strength was limited by patient effort, but was considered to be grossly intact. Her sensory examination revealed no deficits. Her reflexes were of note for 3+ patellar reflexes bilaterally and three beats of ankle clonus bilaterally, but with Babinski reflex plantar bilaterally. Gait examination was limited by pain.

Laboratory data was notable for a white blood cell count of 18,000 per deciliter and liver function tests with elevated alkaline phosphatase (307 units per liter) and direct hyperbilirubinemia (2.7 mg per deciliter) that were elevated above the patient's baseline. A CT scan of the abdomen and pelvis showed a persistently distended gall bladder, but was otherwise unremarkable. The patient was admitted for pain control and leukocytosis. The initial management involved the administration of broad spectrum antibiotics that included coverage of both aerobes and anaerobes for an anticipated hepatobiliary and/or urinary tract source.

Considering the leukocytosis, poorly localized back pain, and hyper-reflexia, a diagnosis of spinal epidural abscess was entertained. However, initially the patient refused diagnostic evaluation (she insisted upon being heavily medicated for even a CT scan). Subsequent attempts at MRI were thwarted

Neurol. Bull. 3: 18-24, 2011
doi:10.7191/neurol_bull.2011.1029

Figure 2: Sagittal T2 weighted image shows the focus of discitis/osteomyelitis centered at the C6-C7 intervertebral disc space (white arrow). There is no abnormal signal within the spinal cord at the level of discitis. The superior extent of the abscess is appreciated at the level of C2 (black arrows).

by the patient's extreme anxiety, even with pharmacological anxiolysis. In the interim she developed fevers, acute renal failure, and tachycardia, findings that were consistent with a severe inflammatory response to infection. On the second day following admission vancomycin was added after reconsideration of the clinical vignette; no culture results were yet back.

On the fifth day of admission, an MRI of the patient's spine was performed, which demonstrated epidural abscess extending from C2 all the way to L4 and discitis/osteomyelitis centered at the C6-C7 disc space; no abnormal signal was present within the spinal cord to suggest spinal cord compression, infection, or injury (Figures 1-4). The patient was sent to the operating room for washout and decompression. However,

Neurol. Bull. 3: 18-24, 2011
doi:10.7191/neurol_bull.2011.1029

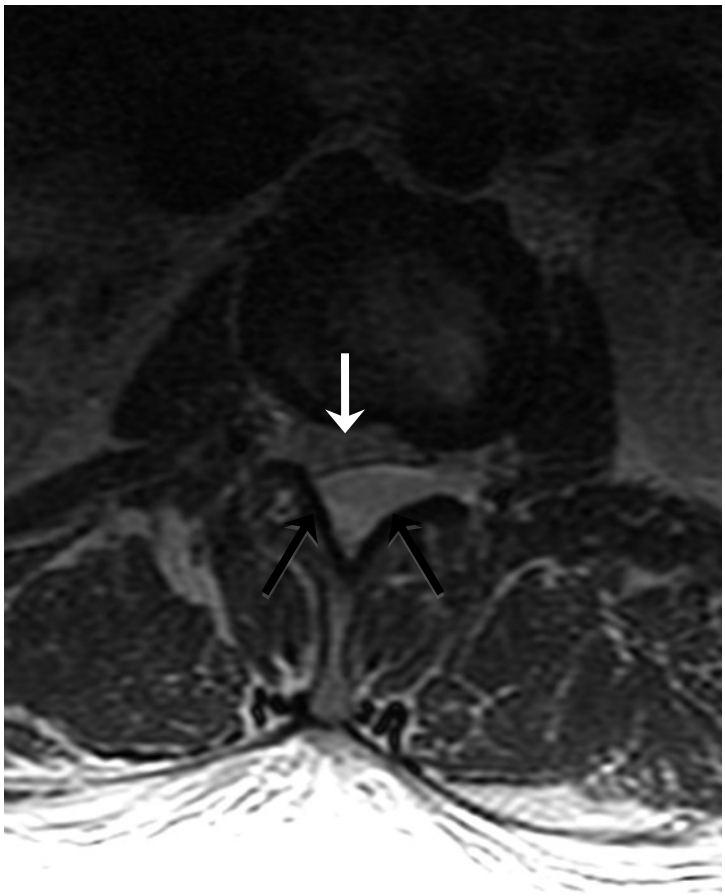

Figure 3: Axial T2 weighted image at the level of the L1-L2 intervertebral disc space again demonstrates the abscess (black arrows) displacing the spinal cord (white arrow) anteriorly and towards the right. No abnormal signal is seen within the spinal cord.

she died of sepsis two days following surgical intervention. The patient's blood cultures eventually grew *Staphylococcus aureus*.

Discussion

This case highlights the devastation that spinal epidural abscesses can wreak with delay in diagnosis, appropriate antibiotic institution, and surgical intervention. The tardive efforts to decompress this patient's spinal cord were essentially futile given the already far advanced inflammatory response that would eventuate in septicemia and death.

The classic presentation of spinal epidural abscess involves the triad of spine pain, fever, and neurologic deficit.[1-3] However, this triad is only present on initial presentation about 13% of the time.[3] As with this patient, the pain is often poorly localized or even not accurately identified as primary back/spine pain. Antipyretic use can confound the fever criteria, which, even in patients who have abstained from the use of antipyretics, is only present 63% of the time.[3] Our patient was afebrile during the first twenty-four hours, but she had an elevated white blood cell count, which sufficiently raised the concern for infection. Lastly, neurological defi-

Neurol. Bull. 3: 18-24, 2011
doi:10.7191/neurol_bull.2011.1029

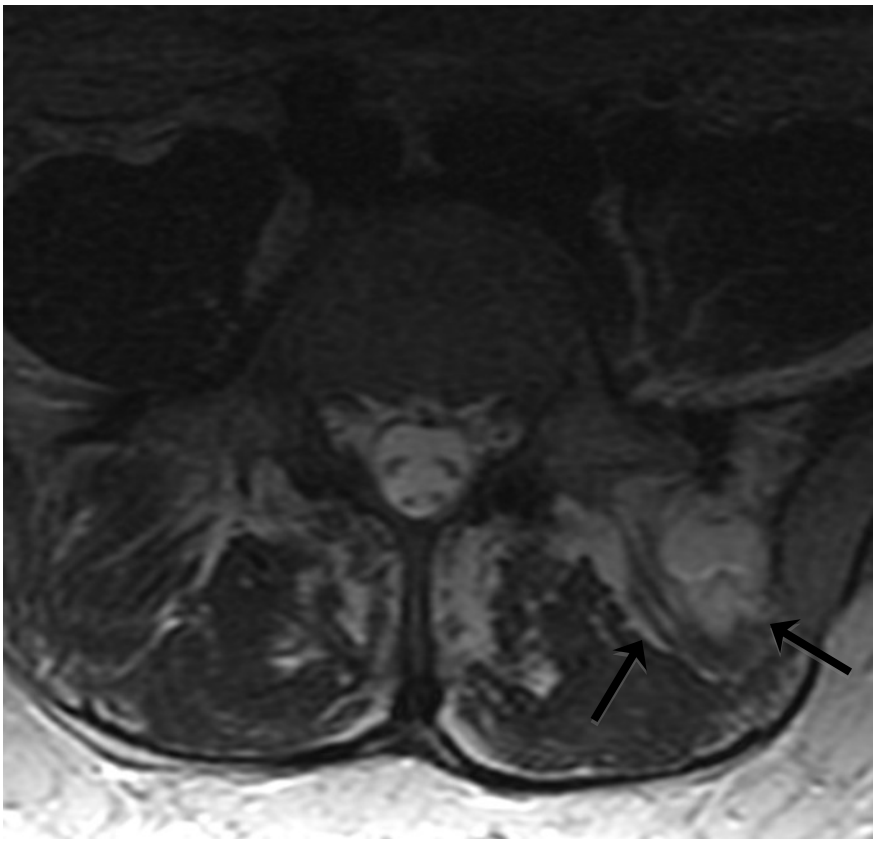

Figure 4: Axial T2 weighted image at the level of the L5 vertebral body shows no further extension of the epidural abscess. In the left paravertebral muscles there is an area of increased T2 signal that represents paraspinal abscess. Note: post-contrast images were limited by motion artifact, and are not presented secondary to poor quality.

cits are only present 44% of the time, and so their absence in this patient is not unusual.[3]

More sensitive than any one component of the classic triad is the presence of any of the key risk factors. Of patients with spinal epidural abscess, 98% have one of the following risk factors: injection drug use, immunocompromise, alcohol abuse, recent spine procedure, distant site of infection, diabetes, indwelling catheter, recent spine fracture, chronic renal failure, or cancer.[2] Specifically, injection drug use, which afflicted our patient, is associated with *Staphylococcus aureus* and *Pseudomonas aeruginosis* epidural abscesses. Had we considered this, we ought to have started anti-MRSA coverage sooner.

The treatment of spinal epidural abscess is well established. Empiric coverage antibiotics should be initiated immediately; a third-generation cephalosporin with vancomycin intravenously and rifampin per os is one acceptable regimen.[5] Unless contraindicated, the patient should undergo surgical decompression and drainage; one exception are patients with paralysis that has been present for

Neurol. Bull. 3: 18-24, 2011
doi:10.7191/neurol_bull.2011.1029

Table 1: Clinical Stages of Spinal Epidural Abscess.[5,7]

Stage	Clinical Signs
I	Back pain, fever, spine tenderness
II	Radicular pain, nuchal rigidity, hyper-reflexia
III	Sensory findings, motor weakness, bowel or bladder dysfunction
IV	Paralysis

longer than three days.[6] Antibiotics should be changed based on the culture results and usually are given for at least six weeks.[6]

However, the difficulty of making the diagnosis of spinal epidural abscess frequently results in delay in treatment and increased morbidity. The preoperative Heusner stage (Table 1) is the most important predictor of the postoperative neurologic outcome.[5,6] Therefore, it is incumbent upon clinicians to make the diagnosis before further neurologic compromise occurs. In one series, only 25% of patients with epidural abscess had the diagnosis considered within the first 24 hours of presentation.[3] In this series, patients with a delay in diagnosis had over five times the risk of residual weakness at discharge compared to those without a delay.

In this patient's case there were several factors that contributed to a delay in diagnosis and effective treatment. The patient's pain was poorly localized on physical examination, perhaps secondary to the epidural abscess spanning nearly the entire spine (C2-L4); however, the absence of spinal tenderness is still surprising. Further, while the diagnosis of spinal epidural abscess was considered within twenty-four hours of presentation, the ability to expeditiously obtain MRI was limited by patient and institutional constraints. This delay resulted in further neurological and septic decompensation of the patient before surgical therapy could be pursued. As well, the initial choice of antibiotics was suboptimal because anti-MRSA coverage was omitted.

Spinal epidural abscess is a devastating disease with high morbidity and mortality. This case highlights some of the difficulties in initiating appropriate therapy emergently to minimize morbidity and mortality. When identifying and treating patients presenting with acute or subacute back pain, we need to entertain the diagnosis of epidural abscess, particularly in the setting of any significant risk factors, and ruthlessly pursue proper work-up even when the classic triad of fever, spine pain, and neurologic deficit is not present.

References

1. Pradilla G, Ardila GP, Hsu W, Rigamonti D. Epidural abscesses of the CNS. Lancet Neurol 2009;8:292-300.
2. Recinos PF, Pradilla G, Crompton P, Thai Q-A, Rigamonti D. Spinal epidural abscess: diagnosis and treatment. Operative Techniques in Neurosurgery 2004;7:188-192.
3. Davis DP, Wold RM, Patel RJ, et al. The clinical presentation and impact of diagnostic delays on emergency department patients with spinal epidural abscess. J Emerg Med 2004;26:285-291.
4. Curry WT, Hoh BL, Amin-Hanjani S,

Neurol. Bull. 3: 18-24, 2011
doi:10.7191/neurol_bull.2011.1029

Eskandar EN. Spinal epidural abscess: clinical presentation, management, and outcome. Surg Neurol 2005;63:364-371.
5. Sendi P, Bregenzer T, Zimmerli W. Spinal epidural abscess in clinical practice. QJM 2008;101:1-12.
6. Darouiche RO. Spinal epidural abscess. N Engl J Med 2006;355:2012-2020.
7. Heusner AP. Nontuberculous spinal epidural infections. N Engl J Med 1948;239:845-854.

Disclosure: the authors report no conflicts of interest.

All content in Neurological Bulletin, unless otherwise noted, is licensed under a Creative Commons Attribution-Noncommercial-Share Alike License
http://creativecommons.org/licenses/by-nc-sa/3.0/
(ISSN 1942-4043)