http://escholarship.umassmed.edu/neurol_bull

Neurol. Bull. 2: 7-11, 2010
doi:10.7191/neurol_bull.2010.1018

NEUROLOGICAL BULLETIN

FEATURING ARTICLES BY TRAINEES IN NEUROLOGY & NEUROSCIENCE

Focal Clonic Seizures Suggest Stroke in a Newborn

Amy A. Gelfand, Hannah C. Glass, Elysa J. Marco, and Donna M. Ferriero

Department of Neurology
University of California - San Francisco, San Francisco, CA

Introduction

Stroke in neonates presents differently than in adults. In most cases, recurrent focal clonic seizure is the only clinical manifestation[1] as neonates with stroke do not usually present with hemiparesis.[2]

Neonatal seizures from non-vascular causes, on the other hand, tend to be multifocal or myoclonic. Determining the etiology of seizure in a neonate is essential as the management and clinical outcome will differ depending on the underlying cause. We present a case of neonatal stroke below.

Case Report

A term baby boy was born by spontaneous vaginal delivery to a 34 year-old G4 P2 to 3 mother. Pregnancy was complicated by insulin-dependent gestational diabetes. There were good fetal movements throughout gestation. Labor was induced for decreased amniotic fluid. The second stage of labor (pushing) lasted for five hours, with mild fetal heart rate decelerations. Meconium stained fluid was noted just prior to delivery. Pediatrics was called after delivery for respiratory depression, however the infant rapidly improved with simple warm, dry stimulation. Apgars were 4 and 8. Birth weight was 4 kg. An umbilical artery cord gas was relatively unremarkable, with a pH of 7.15 and a base deficit of -5.

At approximately 24 hours of life, the pediatrics team noted rhythmic clonic movements of the baby's left upper extremity that lasted 7 minutes and was not extinguishable. The baby was examined by the neurology team shortly thereafter, and had a normal neurologic examination. He then experienced a second 5-7 minute episode of rhythmic left arm jerking that spread to involve the left face.

CSF and electrolytes were normal, as was a head ultrasound. MRI of the brain performed at approximately 48 hours of life showed reduced diffusion in the right postcentral gyrus, compatible with acute infarct of the angular branch of the right middle cerebral artery (Figure 1). There was no evidence of arterial

Correspondence to Amy A. Gelfand: GelfandA@neuropeds.ucsf.edu
Keywords: newborn, ischemic stroke, neonatal seizure

Neurol. Bull. 2: 7-11, 2010
doi:10.7191/neurol_bull.2010.1018

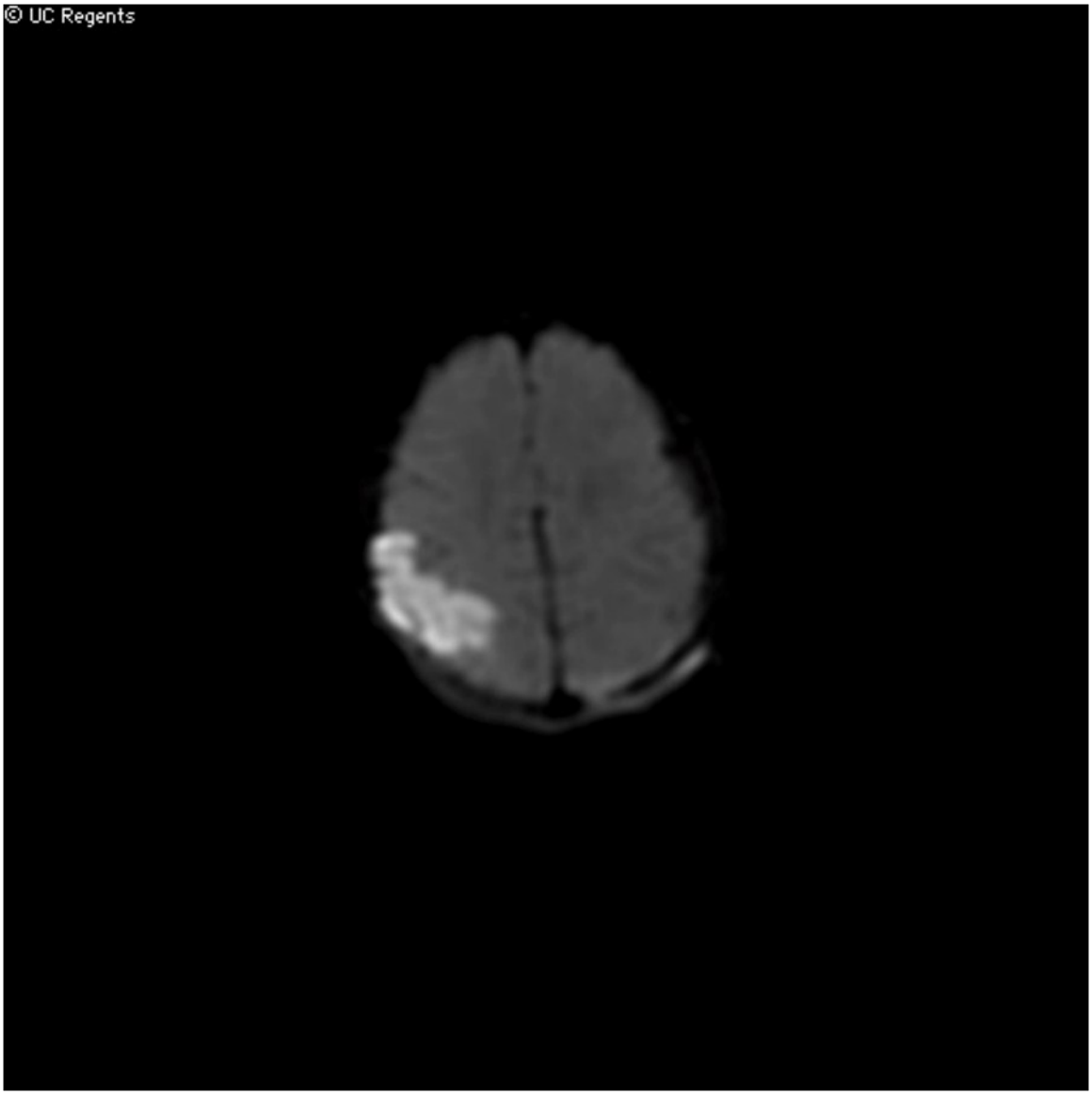

Figure 1: This diffusion-weighted image shows restricted diffusion in the distribution of the angular branch of the right middle cerebral artery, indicating acute infarct.

or venous occlusion on MRA or MRV. EEG captured multiple seizures arising from the right hemisphere both with and without clinical correlate (Figure 2).

The baby was treated with multiple loading doses of phenobarbital and ultimately fosphenytoin. However, by 48 hours of life both the clinical and electrographic seizures had ceased and anticonvulsant drugs were discontinued.

At birth his hematocrit was 63, and rose to 71 by the second day of life. After the stroke was noted, he underwent exchange transfusion, bringing his hematocrit down to 48.

Neurol. Bull. 2: 7-11, 2010
doi:10.7191/neurol_bull.2010.1018

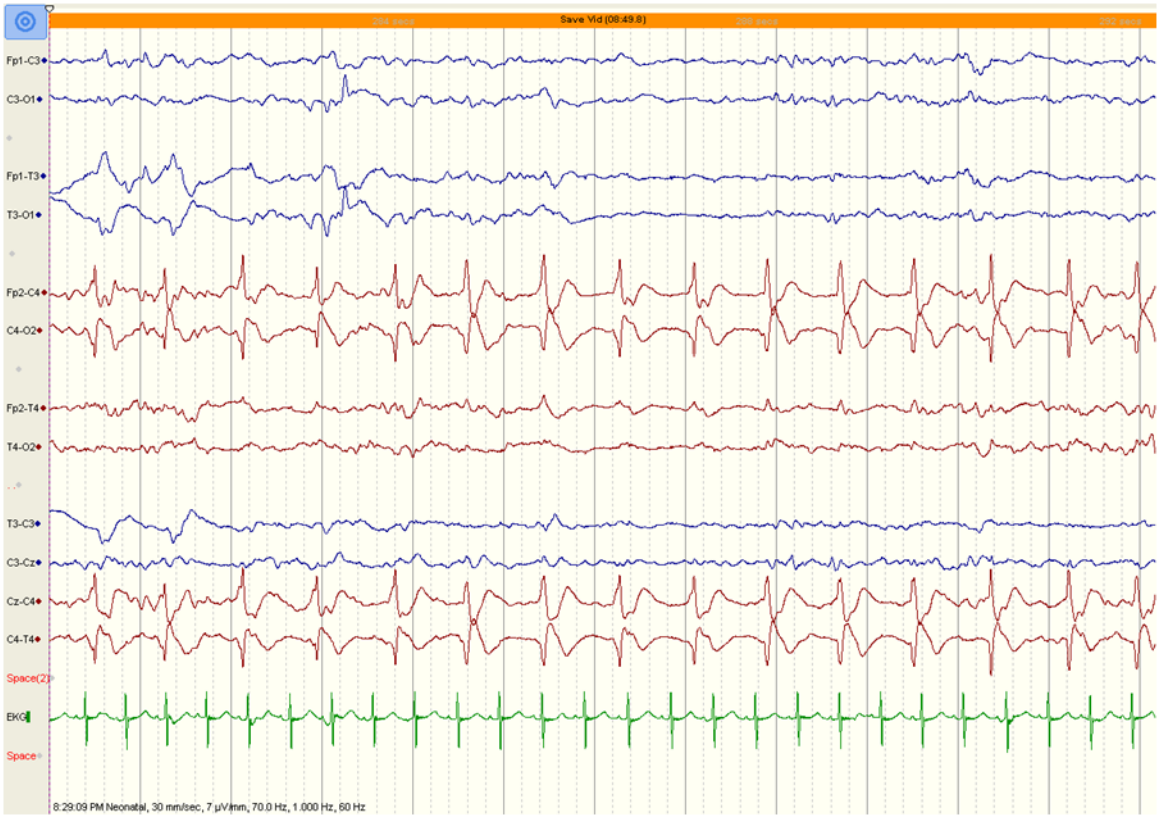

Figure 2: EEG (Neonatal montage) showing evolving spike-wave activity with maximal negativity at C4, which corresponds to the right central region. Clinically, the infant demonstrated rhythmic clonic jerks of the left arm.

Discussion

When presented with a neonate with seizures, both the type of seizure and the timing of seizure onset after birth are helpful in determining the underlying etiology. Seizures secondary to stroke in term neonates usually present after 12 hours of life but within 24-48 hours, while seizures secondary to hypoxic-ischemic injury tend to begin in the first few hours of life, depending on the severity of the insult.[3] Seizures due to neonatal stroke are typically recurrent focal motor seizures[4], while those due to hypoxic-ischemic injury are usually myoclonic or multifocal. Neonates who have suffered a stroke are usually otherwise well appearing, though in some instances there may be signs of encephalopathy.[1]

Treatable causes of neonatal seizures such as hypocalcemia, hypoglycemia and infection, should first be ruled out. Other causes, such as hypoxic-injury or drug withdrawal deserve consideration, but can often be ruled out by the clinical history or presence of multifocal or myoclonic seizures. Cortical malformations, brain abscess, or other mass lesions are rarer etiologies that can mimic stroke. Sei -zures from inborn errors of metabolism often
occur after the newborn has begun to feed.

Neonatal stroke has an incidence of 1:2300 live births, higher than the annual rate of adult large vessel stroke.[5] Approximately two

Neurol. Bull. 2: 7-11, 2010
doi:10.7191/neurol_bull.2010.1018

-thirds of perinatal strokes are arterial, though hemorrhagic and venous infarcts also occur.[5] There is a male predominance and left-sided lesions are more common. The middle cerebral artery and its branches are most commonly implicated.[6]

Antepartum risk factors for arterial stroke include preeclampsia, history of infertility, maternal cocaine use, oligohydramnios and decreased fetal movements. Intra-partum risk factors include prolonged second stage of labor, fetal distress, prolonged rupture of membranes, and chorioamnionitis.[1,7] Several of these factors may relate to an inflammatory state in the placenta that predisposes to clot formation. Other potential embolic sources for arterial stroke in neonates include involuting fetal vessels, such as a thrombus in the closing dutus arteriosus. Neonatal risk factors include polycythemia, meningitis or other intracranial infections, complex congenital heart disease, and sepsis.[1,5] Hypercoagulable states, such as Factor V Leiden mutation or Factor II, are common, however they are usually not the only risk factor present.[8,9] The risk of neonatal stroke increases with the number of risk factors.[7]

Head ultrasound is useful for detecting intracerebral hemorrhage. However, to rule out ischemic stroke, MRI with diffusion-weighted imaging is necessary. Vascular imaging is important and both MRA and MRV should be performed. MRV is needed to rule-out sinus venous thrombosis leading to venous infarct or hemorrhage. Occasionally, newborn stroke will be due to a carotid dissection[5] and fat-saturated imaging may be required for diagnosis. CT is less sensitive for detecting ischemic infarct and exposes the infant to radiation and, as in adults, is not the imaging modality of choice for newborns with suspected stroke.

Thrombolytics are not currently used to treat arterial stroke in neonates. Anticoagulation and aspirin therapy are also not indicated in the absence of a documented ongoing cardio-embolic source.[10] Polycythemia and dehydration should be corrected to optimize blood flow to the infarcted territory. Although hypercoagulable mutations may be present, anticoagulation therapy is usually not indicated as stroke recurrence risk is very low.[8] Therefore, the clinical benefit of testing for these remains unclear.

Seizures secondary to neonatal stroke may require multiple doses of anti-epileptic drugs before both clinical and electrographic seizures are eliminated. Continuous EEG monitoring is needed because of the clinical-electrographic dissociation that often occurs with phenobarbital therapy, the drug most commonly used to treat neonatal seizures. Within a week of life, the seizures usually cease. Often the anti-epileptics are weaned off prior to discharge.

Both motor and cognitive outcome can be affected by perinatal stroke. A cortical infarct that spares the basal ganglia and posterior limb of the internal capsule, such as in this infant, carries a lower risk of motor impairment.[6] Similarly, an infarct that involves only one or two of these regions (cortex, basal ganglia, and posterior limb of the internal capsule) has a better prognosis.[11] Lesions that involve subcortical regions may be associated with worse cognitive outcome.[12] Babies who present in the neonatal period often have a better outcome than children with presumed perinatal stroke who are well in the neonatal period, but present later in infancy with early hand preference or seizure, as children who present later have deficits that are more likely to persist.[14] Infants with neonatal stroke should be followed closely by a child neurologist so that early referrals for

Neurol. Bull. 2: 7-11, 2010
doi:10.7191/neurol_bull.2010.1018

rehabilitative or educational services can be made.

References

1. Wu YW, Lynch JK, Nelson KB. Perinatal arterial stroke: understanding mechanisms and outcomes. Semin Neurol 2005;25:424-434.
2. Guzzetta A, Mercuri E, Rapisardi G, et al. General movements detect early signs of hemiplegia in term infants with neonatal cerebral infarction. Neuropediatrics 2003;34:61-66.
3. Ferriero DM. Neonatal brain injury. N Engl J Med 2004;351:1985-1995.
4. Rafay MF, Cortez MA, de Veber GA, et al. Predictive value of clinical and EEG features in the diagnosis of stroke and hypoxic ischemic encephalopathy in neonates with seizures. Stroke 2009;40:2402-2407.
5. Kirton A, deVeber G. Advances in perinatal ischemic stroke. Pediatr Neurol 2009;40:205-214.
6. Lee J, Croen LA, Lindan C, et al. Predictors of outcome in perinatal arterial stroke: a population-based study. Ann Neurol 2005;58:303-308.
7. Lee J, Croen LA, Backstrand KH, et al. Maternal and infant characteristics associated with perinatal arterial stroke in the infant. JAMA 2005;293:723-729.
8. Grabowski EF, Buonanno FS, Krishnamoorthy K. Prothrombotic risk factors in the evaluation and management of perinatal stroke. Semin Perinatol 2007;31:243-249.
9. Kenet G, Lutkhoff LK, Albisetti M, et al. Impact of thrombophilia on risk of arterial ischemic stroke or cerebral sinovenous thrombosis in neonates and children: a systematic review and meta-analysis of observational studies. Circulation 2010;121:1838-1847.
10. Monagle P, Chalmers E, Chan A, et al. Antithrombotic therapy in neonates and children: American College of Chest Physicians Evidence-Based Clinical Practice Guidelines (8th Edition). Chest 2008;133:887S-968S.
11. Boardman JP, Ganesan V, Rutherford MA, Saunders DE, Mercuri E, Cowan F. Magnetic resonance image correlates of hemiparesis after neonatal and childhood middle cerebral artery stroke. Pediatrics 2005;115:321-326.
12. Westmacott R, Askalan R, MacGregor D, Anderson P, Deveber G. Cognitive outcome following unilateral arterial ischaemic stroke in childhood: effects of age at stroke and lesion location. Dev Med Child Neurol 2010;52:386-393.
13. Bava S, Archibald SL, Trauner DA. Brain structure in prenatal stroke: quantitative magnetic resonance imaging (MRI) analysis. J Child Neurol 2007;22:841-847.
14. Golomb MR. Outcomes of perinatal arterial ischemic stroke and cerebral sinovenous thrombosis. Semin Fetal Neonatal Med 2009;14:318-322.

Disclosure: the authors report no conflicts of interest.

All content in Neurological Bulletin, unless otherwise noted, is licensed under a Creative Commons Attribution-Noncommercial-Share Alike License http://creativecommons.org/licenses/by-nc-sa/3.0/
(ISSN 1942-4043)