http://escholarship.umassmed.edu/neurol_bull

Neurol. Bull. 1: 14-16, 2009
doi:10.7191/neurol_bull.2009.1003

NEUROLOGICAL BULLETIN

FEATURING ARTICLES BY TRAINEES IN NEUROLOGY & NEUROSCIENCE

A Lilt of Finland in Worcester, Massachusetts: A Case of Foreign Accent Syndrome

Richard P. Goddeau, Jr.* and Ann Mitchell

Department of Neurology
University of Massachusetts Medical School, Worcester, MA

Foreign accent syndrome (FAS) is a rare speech output disorder characterized by articulation of speech perceived by listeners (often including the patient) as sounding "foreign." From Monrad-Krohn's seminal paper in 1947 [1] describing a Norwegian woman who, as a result of head trauma, began speaking with a German-sounding accent, several cases of FAS have been reported. Usually occurring in consequence to some brain dysfunction, often stroke, two distinct types of FAS are described: [1] acquisition of an accent the patient was previously unfamiliar with or unexposed to, the unlearned foreign accent, and [2] the reversion to a previously learned accent. In addition to ischemic and hemorrhagic stroke,[2-5] traumatic brain injury,[3,6] multiple sclerosis,[7] and the herald of primary progressive aphasia[8] have all been reported as causes of the foreign accent syndrome.

Here we report a case of reversion to a previously learned foreign accent in a patient with acute ischemic stroke. We review data on anatomic localization in this subtype and how it informs on the nature of this unusual disorder.

Case Report

A 57 year old previously healthy right-handed man awoke with mild right arm and facial weakness and a subjective sense of mild confusion. He presented to the emergency room at the University of Massachusetts Medical Center several hours later, after driving to work where colleagues observed that he was dysphasic, having expressive difficulty. During the initial evaluation, the dysphasia resolved but the patient was noted to have dysprosodia, described by multiple examiners and agreed by the patient as sounding like English spoken with a Finnish accent. The patient, born and raised in Gardner, Massachusetts, initially learned English and Finnish. His parents and several friends were of Finnish extraction and he had visited Finland twice. He acquired fluency only in English, speaking with a "Massachusetts" accent.

On clinical examination, the patient was hypertensive at 229/77. Remaining vital signs were normal. General medical exam was significant only for an irregularly irregular

**Present Address:* Dept. Neurology, Beth Israel Deaconess Hospital, Boston, MA
Correspondence to Richard P. Goddeau, Jr.: rgoddeau@bidmc.harvard.edu
Keywords: foreign accent syndrome, left precentral gyrus

Neurol. Bull. 1: 14-16, 2009
doi:10.7191/neurol_bull.2009.1003

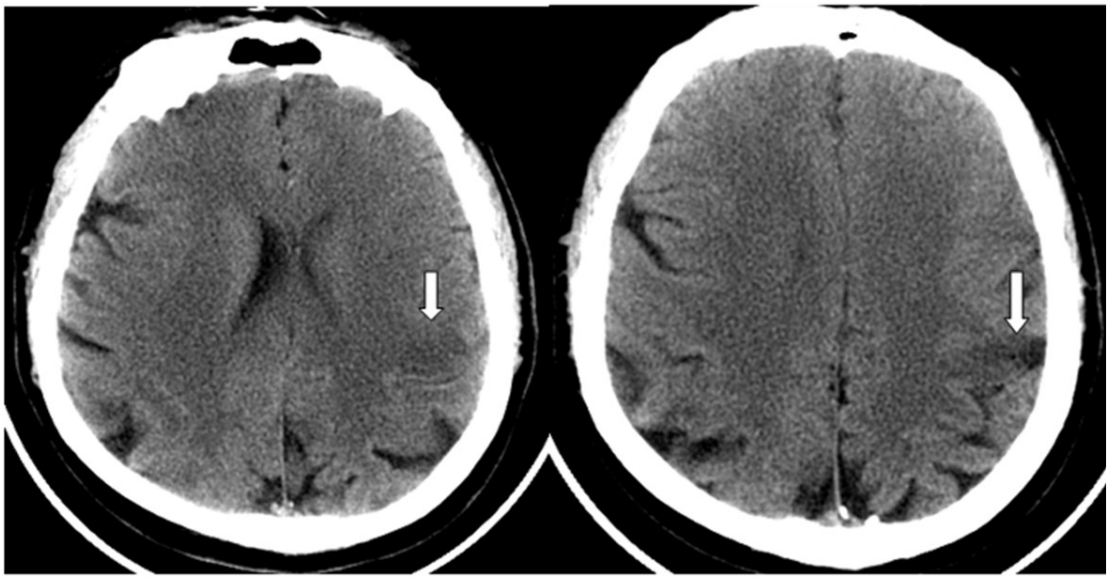

Figure 1: Noncontrast head CT with serial slices at and immediately cephalad to apex of body of the lateral ventricle showing hypodensity in left precentral gyrus.

heart rhythm on auscultation. Neurologically, the patient was alert and oriented. He displayed a mild labial-type dysarthria and aprosodia in casual speech and singing and was assessed by multiple neurologists as having abnormal intonation, inflection and pauses for a native English speaker from Massachusetts (see Audio file). Motor exam showed normal strength testing but was significant for a mild pronator drift of the right arm. Sensory, cerebellar and reflex exam were unremarkable.

Diagnostic evaluation included an electrocardiogram which revealed atrial fibrillation and a noncontrast head CT scan (NCCT) showing a small area of hypodensity in the left precentral gyrus (Figure 1). Subsequent brain MRI confirmed clinical and NCCT findings, showing two small areas of restricted diffusion in the left motor cortex and right cerebellar hemisphere. Telemetry monitoring disclosed atrial fibrillation.

The patient was discharged on oral anticoagulation. Over the ensuing several weeks, his accent regressed to his "normal" Massachusetts accent.

Discussion

The dysprosodic features that characterize FAS include aberrancies of word or sentence accentation, intonation, speech rate or rhythm.[9] In some reports, the acquired accent is discerned to represent a distinct accent of a non-native speaker, even when assessed by native speakers of the area from where the accent would have been acquired naturally.[4] However, other reports have disclosed dissenting opinions amongst listeners as to "where" the accent would have originated.[6,8] In our patient, one listener thought the accent sounded "Russian"; several others, including the patient, believed it to be "Norwegian." In any case, his speech rate was thought to be slowed, intonation flatter (than American or Massachusetts-dialect English), with unexpected sentence accentations.

The stroke lesion localization in the domi-

Neurol. Bull. 1: 14-16, 2009
doi:10.7191/neurol_bull.2009.1003

nant (left) precentral gyrus in our patient is consistent with prior reports. In the literature review of Edwards and associates,[3] 7 of 22 authors described a culprit lesion in the left motor cortex. Interestingly, all were cases of unlearned FAS. Amongst previously learned FAS, parietal and basal ganglia more than capsular lesions predominate;[3,5] amongst unlearned FAS, left motor or pre-motor and parietal lesions predominate. However, basal ganglia, capsular, callosal, diffuse, and even right-sided pre- and post-central gyrus lesions have been reported.[2-4,6,7]

Although most often transient, because FAS occurs for weeks to months, it is thought to represent a discrete phenomenology, rather than an articulatory compensatory mechanism for stroke (or other lesion) related dysarthria. Furthermore, the speech in FAS is not always dysarthric, dyspraxic, or dysphasic. Yet, although several specific regions have been repeatedly identified, there has been no consensus lesion. Furthermore, many patients with similar such lesions do not display this speech patterning. A precise neuroanatomic explanation may not be feasible.

Physiologically, disruption of neuronal networks for linguistic prosody or disinhibition of previously suppressed accent templates amongst a universal inventory of sounds has been suggested.[3,4,6] For previously learned FAS, it is possible that bilingual or bidialectical prosodic information is stored in discrete cortical areas, resulting in re-emergence of formerly suppressed speech patterns with a lesion damaging the cortical area or pathways subserving the dominant speech patterns.

References

1. Monrad-Krohn GH. Dysprosody or altered melody of language. Brain 1947;70:405-415.
2. Coughlan T, Lawson S, O'Neill D. French without tears? Foreign accent syndrome. J R Soc Med 2004;97:242-243.
3. Edwards RJ, Patel NK, Pople IK. Foreign accent following brain injury: syndrome or epiphenomenon? Eur Neurol 2005;53:87-91.
4. Hall DA, Anderson CA, Filley CM, Newcombe J, Hughes RL. A French accent after corpus callosum infarct. Neurology 2003;60:1551-1552.
5. Roth EJ, Fink K, Cherney LR, Hall KD. Reversion to a previously learned foreign accent after stroke. Arch Phys Med Rehabil 1997;78:550-552.
6. Moonis M, Swearer JM, Blumstein SE, et al. Foreign accent syndrome following a closed head injury: Perfusion deficit on single photon emission tomography with normal magnetic resonance imaging. Neuropsychiatry Neuropsychology and Behavioral Neurology 1996;9:272-279.
7. Bakker JI, Apeldoorn S, Metz LM. Foreign accent syndrome in a patient with multiple sclerosis. Can J Neurol Sci 2004;31:271-272.
8. Luzzi S, Viticchi G, Piccirilli M, et al. Foreign accent syndrome as the initial sign of primary progressive aphasia. J Neurol Neurosurg Psychiatry 2008;79:79-81.
9. Verhoeven J, Marien P. Prosody and Foreign Accent Syndrome: a Comparison of Pre- and Post-stroke Speech (poster). Presented at the Speech Prosody 2004 International Conference; March 23-26, 2004; Nara, Japan.

Disclosure: the authors report no conflicts of interest.

All content in Neurological Bulletin, unless otherwise noted, is licensed under a Creative Commons Attribution-Noncommercial-Share Alike License http://creativecommons.org/licenses/by-nc-sa/3.0/
(ISSN 1942-4043)